

陕西省发展和改革委员会¹

2023 年度创新平台建设项目²

项目名称： 微创化手术智能导航平台建设³

建设单位： 西安交通大学第一附属医院⁴

申请单位： 西安交通大学⁵

2022 年 12 月 29 日⁶

一、项目基本情况¹

(一) 项目名称：微创化手术智能导航平台建设²

(二) 承担单位及基本情况³

1. 单位一般情况⁴

(1) 单位名称：西安交通大学第一附属医院⁵

(2) 注册地址：陕西省西安市雁塔区雁塔西路 277 号

(3) 成立日期：1956 年

(4) 所有制性质：国家事业单位

(5) 主营业务：

医院是集医疗、教学、科研、康复、预防保健为一体国家卫生健康委员会委⁶管的大型综合性三级甲等医院。医院有医疗医技科室 57 个，其中医疗 46 个，医技科室 11 个。科研平台有国家联合地方工程研究中心、教育部重点实验室和 2 个陕西省重点实验室，8 个陕西省临床医学研究中心，2 个陕西省工程研究中心等。秉承“厚德、博爱、精医、卓越”之院训，为人民身体健康提供医疗与护理保健服务。

2. 人员情况⁷

依托单位职工总人数为 5185 人，其中高级专业技术人员 782 名。⁸

项目承担单位精准外科与再生医学国家地方联合研究中心在磁外科技术的⁹应用与发展、磁性纳米材料及永磁材料研制、磁生物学效应、组织工程平台关键技术研究等方面，经过多年建设，初步形成“产学研”结合的市场化运行机制，并产生一定的示范效应，逐渐形成了一支以项目负责人为学科带头人的研究与工程技术人才队伍。

中心现有研究人员 81 人，其中博士 54 人，硕士 25 人，本科 2 人；教授 28¹⁰人，副教授 12 人，中级职称 23 人，初级职称 18 人；科研人员 56 人，技术人员 22 人，管理人员 3 人。

3. 经济状况¹

近三年的销售收入、利润、固定资产、资产负债率、银行信用等级列表如下：²

| | 2019 年 | 2020 年 | 2021 年 |
|------------|--------|--------|--------|
| 企业总资产（万元） | 561011 | 592004 | 745137 |
| 固定资产净值（万元） | 153783 | 154210 | 221363 |
| 资产负债率 | 42.17% | 44.81% | 43.61% |
| 银行信用等级 | 四级 | | |

4. 项目负责人⁴

吕毅，一级主任医师，二级教授，博士生导师，教育部创新团队学科带头人，享受国务院特殊津贴，卫生部有特殊贡献的中青年专家，陕西省“三秦学者”特聘教授、“西安市十佳创新人物”。现任西安交通大学副校长、第一附属医院院长、先进外科技术与工程研究所所长、一附院肝胆病院副院长，陕西省再生医学与外科工程研究中心主任、精准外科与再生医学国家地方联合工程研究中心主任。兼任教育部临床医学类专业教学指导委员会副主任委员、中华医学会外科学分会委员、外科手术学组副组长等。担任《临床医学研究与实践》主编、《中华肝胆外科杂志》副总编，《中华肝脏外科手术学杂志电子版》副主编等 10 多种杂志编委。曾获全国五一劳动奖章、陕西省五四青年奖章、陕西省道德模范（敬业奉献类）等。第一完成人获国家科技进步二等奖 1 项、省部级科技一等奖 6 项。主持科技部重点研发计划项目、国家自然科学基金重点项目、国家重大科学仪器研制项目、重大仪器专项、卫生部临床学科重点建设项目及省部级等项目 30 项。主编、参编教材、专著 14 部，主译专著 3 部。发表学术论文 680 篇，SCI 收录 244 篇。授权国家发明专利 56 项，软件著作权 1 项，授权美国专利 1 项。⁵

刘学民，主任医师，教授，肝脏外科专家。现任西安交大一附院腔镜中心主任、陕西省再生医学与外科工程研究中心副主任。在肝脏外科全方位进入微创时代的大背景下，创建西北腔镜肝联盟并担任联盟理事长，肝脏外科微创治疗水平在西北地区处于引领水平、国内先进水平。自 2001 年起开始从事临床肝脏移植工作，参与完成各种肝脏移植 1000 余例，积累了丰富的肝脏外科手术及围手术⁶

期管理的经验。可为肝脏疾病患者提供从诊断、综合治疗到肝脏移植的全方位服务。¹研究方向：医工交叉外科技术创新与器械研发、肝脏疾病综合治疗、磁外科技术，尤其擅长肝脏外科与肝脏移植。任中国研究型医院学会普通外科专业委员会委员、中国研究型医院学会肝胆胰专业委员会肝癌学组委员、陕西省抗癌协会肝胆胰专业委员会肝癌学组组长、陕西省抗癌协会肝胆胰专业委员会常委、陕西肿瘤防治联盟肝癌专业委员会副主任委员、西北腔镜肝联盟理事长、丝路肝癌防治联盟副理事长、中华医学会陕西省分会器官移植分会委员、中国医师协会器官移植分会活体移植学组委员、陕西省医师协会器官移植医师分会常委等。获中华医学科技、教育部技术发明、陕西省科学技术进步、陕西省高校科技一等奖 5 项。获发明专利 10 余项。发表文章 208 篇，其中 SCI 56 篇。主持和参与各级项目 20 项。

（三）建设背景与目标²

建设背景：³

在健康中国战略的基础上，党的二十大再次强调要完善科技创新体系，坚持四个面向，加快实现高水平科技自立自强。人民至上，生命至上，把保障人民健康放在优先发展的战略位置，加强医院数字化、信息化建设。⁴

随着人工智能技术的飞速发展，人工智能技术及算法已在医学影像、临床决策支持、病理分析等众多医疗领域有所应用。国内众多三甲医院也已启动智能诊疗助手、智能影像识别等人工智能技术的试点工作。但目前人工智能在医疗领域的应用仍主要集中于单场景医疗任务辅助，临床医疗相关的精准化人工智能诊疗体系建设仍处于初步探索阶段，基于大样本的临床数据挖掘与手术智能辅助是当前临床医疗数字化的发展热点和重点。⁵

2012 年经陕西省发展改革委员会批准建设“陕西省再生医学与外科工程研究中心”。在此基础上，2018 年 1 月经国家发展和改革委员会批准建设“精准外科与再生医学国家地方联合工程研究中心”。中心秉持以临床问题为导向、以理工医学科交叉外科技术创新为特色、以服务患者为宗旨，坚持“临床问题—实验研究—临床应用”的医工结合外科创新之路，培养了一大批具有创新思维、创新能力的复合型医学人才。主要研究方向有：1. 人工智能与智慧医疗；2. 基于声、光、电、磁的外科技术创新与器械、设备研发；3. 新型功能材料临床应用研究；⁶

4. 组织工程修复重建与肝脏移植；5. 外科重症与加速康复外科技术。¹

中心已构建集**术前**病灶精准定位导航及智能路径规划、**微创术中**手术三维导航定位模块及磁锚定荧光腔镜影像采集设备、**术后**图文手术记录生成模块于一体的**手术导航平台**及配套人才培养体系。进一步实现精准、微创理念下融合术前患者多模态临床诊疗大数据的术中 AR 实时智能导航系统，搭建手术智能导航平台，制定术中智能导航相关规范，并完成临床试点应用，数字化、信息化、智能化赋能外科诊疗发展

建设目标：³

1. 聚焦国家医药卫生与健康领域的重大需求，基于医疗大数据，研发**精准化、数字化手术智能导航体系**，有效提高手术患者的**远期生存率与生活质量**。⁴

2. 针对医疗资源紧缺，尤其是创新性复合型医学人才严重短缺，应用**智能手术导航平台**，搭建**青年医生及医学生创新培养平台**，为保障人民生命健康培养一支**有创新、能战斗的人才队伍**。

3. 平台依托建设单位，将建成**人工智能与智慧医疗的示范基地**，牵头制定行业、产业等相关标准，为医院、高校、科研院所及企业，甚至政府提供相关技术支持和平台服务，促进**创新链和产业链融合**。

（四）建设地点、建设规模⁵

建设地点：西安交通大学雁塔校区（含第一附属医院）。⁶

建设规模：拟建成集术前规划、术中导航等相关智能设备研发、测试一体化⁷平台，面积约 500 平方米。

（五）建设内容⁸

外科手术切除仍是肿瘤治疗的主要手段，在以微创为核心的精准外科理念下，⁹新建的微创化手术智能导航平台，通过最新的人工智能分析手段，利用多尺度多模态信息融合的大数据分析方法，辅助外科医生对手术患者进行术前方案规划、术中智能导航，提高患者肿瘤精准治疗和生活质量。同时，建成符合现代医学发展及临床需求的医学创新人才培养平台。

1. 术前多模态患者数据个性化手术方案定制系统¹⁰

不同的患者因个体解剖差异，手术的入路与规划也不完全相同。如图 1 所示，¹¹

根据每位患者术前的多层螺旋 CT 平扫与磁共振成像影像学检查数据对其进行手术目标脏器三维重建，利用三维重建模型明确手术部位的脉管空间系统和重要血管与神经组织间关系；同时通过血管流域分析精准化划分解剖区域，进行脏器面积与功能的计算评估，最大程度上保留有效功能区并做到肿瘤完整切除；虚拟化的重建系统可以直接内置于 AR 设备中，在术前不断进行手术路径与切除方式规划，降低主刀术者对于既往经验的依赖。同时功能性的人工智能分析在明确手术入路基础上还可以利用影像组学预测潜在的血管癌栓、微血管浸润、术中重要组织脏器粘连和腹壁侵犯转移等特殊事件的发生，从而优化术中流程，为每位患者在术前制定精准化、流程化的综合诊疗方案，争取最大的临床获益。

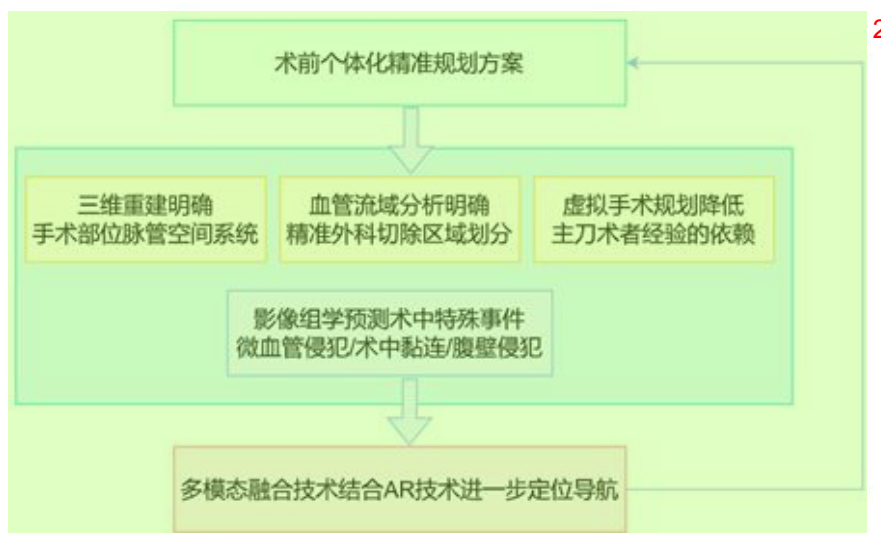


图 1 术前多模态数据精准规划个性化方案

(1) 三维术前影像智慧可视化评估模块

对患者术前的临床资料、血清学化验指标、影像学检查指标如腹部平扫+增强计算机断层扫描(computerized tomography, CT)、腹部平扫+增强核磁共振等归纳收集，搭建手术切除部位系统性的三维重建模块，利用目前最新的光线投射法，产生高质量模型明确手术过程中重要组织与脉管边界。现有的系统可以自动配准多期 CT 数据，无需手动切换多期相增强影像，方便医生多维度定量评估和分析病灶，根据相关数据自动计算病灶体积、长短径。如图 2 所示，以肝胆外科为例，该系统可以量化病灶在各肝段的占比，同步自动计算肝脏体积、肝叶比例、肝脾比等量化指标，结合肝脏形态进行智能分析，动态三维渲染后清晰地展示肝脏形态、肿瘤位置与血管流域，利用流域分析技术精准制定手术切除范围，定制手术

规划。¹

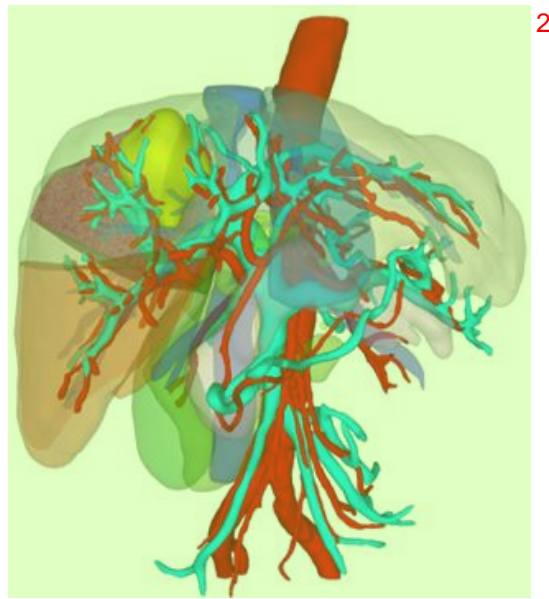


图 2 术前三维重建模型³

对于解剖性肝切除的病人，如图 3 所示，术前普美显增强 MR 可明确患者病灶数量及位置，术前数字化精准定量评估，制定手术切除区域，计算残余肝脏面积。对于患者的手术入路应综合考虑切肝线与平面，循着肝段之间的乏血管间隙来切除，有效避免剩余肝脏脉管结构损伤。针对肿瘤侵犯范围大、预计切除后残余肝脏体积不足的肝脏占位患者，通过术前评估后可利用多期手术来进行联合肝脏离断及门脉结扎的分次肝切除术 (associating liver partition and portal vein ligation for staged hepatectomy, ALPPS)，先通过一期手术将有占位侵犯的肝脏与正常肝脏离断并结扎患侧门静脉，待健侧肝脏长到足够体积后，行二期手术彻底切除患侧肝脏。

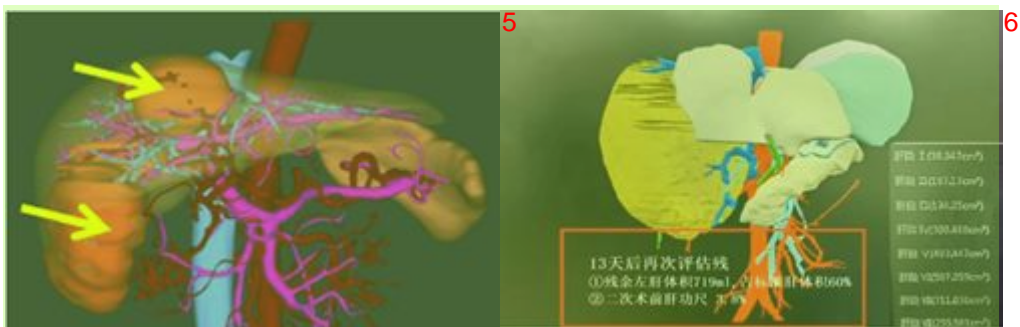


图 3 术前多阶段病灶三维重建显像⁷

(2) 全手术流程 AR 术前模拟模块¹

增强现实(Augmented Reality, AR)是指透过摄影机影像的位置及角度精算并加上图像分析技术,让屏幕上的虚拟世界能够与现实世界场景进行结合与交互的技术。在各科室医生中,外科医生是最早采用可以增强手术和患者体验技术工具的人。其应用的方面包括手术规划、手术广播和记录、解剖评估、远程指导和医学教育。将建好的模型导入 AR 中,实时、高精度地为外科医生展示重建模型,外科医生可以在术前通过高仿真全脏器训练系统初步训练来模拟手术流程,将腹部模型进行术前影像建模后与操作器械共同置于一个坐标系中,通过验证算法对特征点进行提取和处理,在清晰的虚拟手术视界中不断摸索评估最佳的手术入路,确定手术时患者的体位及拟定穿刺孔的位置、拟切除范围以及处理重要血管的方式、游离脏器的次序方向与实质脏器的离断方式与角度,制定手术中的解剖路标,减少因术中无效步骤给患者带来的创伤,有效缩短手术时间。同时也可以有效减少主刀术者对手术实践经验的依赖,加速学习成长曲线。²

(3) 以术前影像组学为基础的术中特殊事件预测模块³

目前相关的影像组学技术在原发性肝癌领域已经有大量的应用,可在术前采用 radiomics 技术定量分析术前影像 CT 数据中的多种影像特征。将影像特征与 BMI、MELD、AFP 等临床指标相结合综合构建一套预测模型,即可实现有效地预测肿瘤组织出现微血管侵犯(MVI)、术中组织粘连、胆管异常、淋巴结转移等特殊事件的发生情况,来更好的方便术者精准规划手术路径,规避相关风险。该预测模型不仅可以辅助外科医生制定一套较全面且精细化的手术方案,而且还可以提高患者的总体预后。⁴

2. 术中智能辅助决策系统——人工智能术中导航医疗设备⁵

平台利用人工智能为临床外科手术赋能,以精准、实时理念为核心,提供了一套术中全流程的智能辅助决策模块。利用本课题组全球首创的微创图文手术记录系统,持续稳定收集了多中心多区域大型三甲医院的大量腔镜手术视频数据,并在资深临床专家指导下建立术中影像数据集,在其基础上进行算法构建,包括手术过程识别、手术器械识别、解剖结构识别、手术动作识别、操作安全性评估、术中重要特殊事件识别等多种应用场景,建立了一套微创内镜术中实时分析解剖结构部位的智能分析识别系统,以及以术中图像去雾优化手术步骤的术中影像智能增强系统。并且利用术中超声、双通道磁锚定荧光成像设备建立功能性荧光成⁶

像系统，结合术前三维重建 AR 模型，在术中根据特殊解剖位置、功能性解剖线的呈现等多模态方式优化手术路径，避免术中相关并发症。

(1) 微创术中人工智能医疗辅助硬件加速模块²

目前已完成适用于肝胆胰、胃肠等微创术中人工智能医疗辅助硬件加速系统的开发工作。基于医院端现有数字化平台建设，在医院端布置边缘计算加速服务器，缩短术中实时数据传输时间，实现术中实时医疗辅助，通过内网进行数据传输和分析保障医疗数据安全，实现手术记录的及时性、唯一性，杜绝手术记录中大量复制现象的出现。经语义分割处理后将术中视频回传至手术室大屏幕，辅助医生进行术中决策。同时，医院端布置边缘计算人工智能加速服务器可以与多中心训练云端进行安全互通，实现微创术中影像医疗辅助算法模型的快速更新，为临床医生手术实施提供更为精确的辅助。

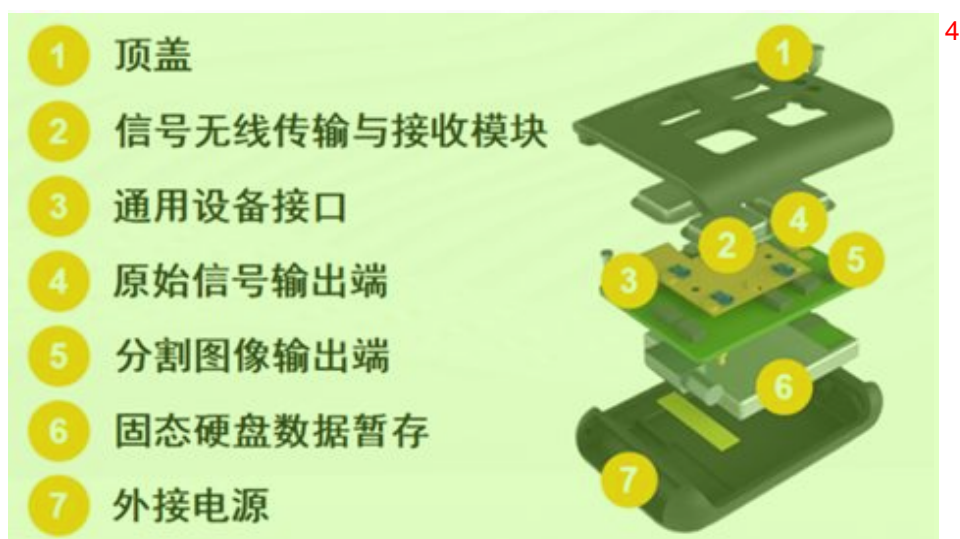

图 4 微创手术腔镜影像记录分析设备⁵

项目实现了微创术中影像记录分析软硬件系统搭建，并且在医院端构建边缘计算人工智能加速服务器硬件平台，对采集到的术中影像进行硬件加速，满足术中实时导航的低延迟及算力需求。如图 4 所示，本平台自主设计研发微创手术腔镜影像记录分析仪，包含信号无线传输与接收模块、通用设备接口、原始信号输出端、分割图像输出端、固态硬盘等重要组成部分，其可有效提高术中导航与决策的有效性与准确性，减小临床外科医生工作负担，自动持久获取真实术中影像数据，自动构建临床术中影像数据库。

为满足医院内部署边缘计算人工智能加速服务器硬件平台对术中影像检测⁷

的实时性要求，选择以剪枝量化后的深度 YunTrans 网络作为基础检测算法，对于术中视频影像进行实时检测。如下图 5 所示为项目定制的术中实时影像目标检测网络相关结构示意图。

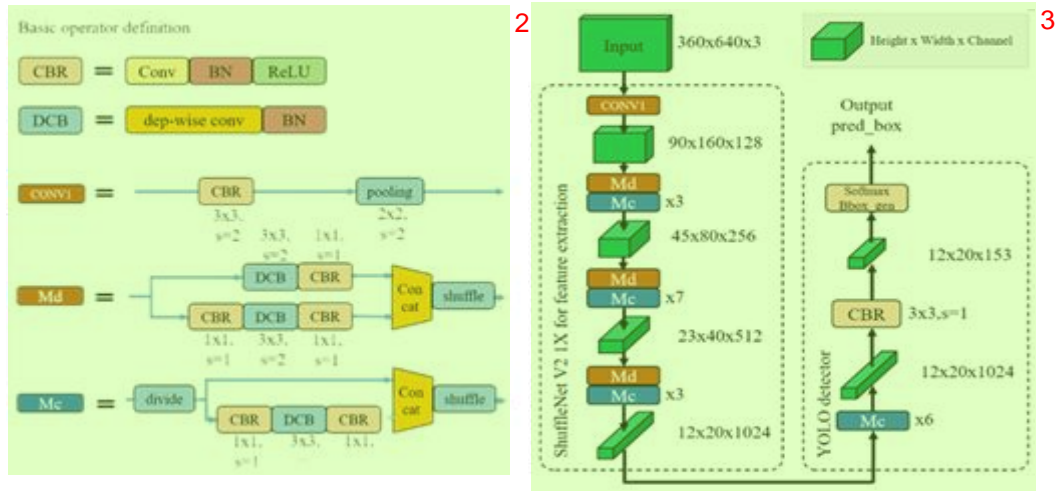


图 5 部署端医疗影像人工智能识别网络结构示意图

微创术中影像记录分析设备中搭载的医疗影像预处理加速硬件为通用加速器硬件 HiPU，其特殊的硬件结构可以更有效地调度运算整体流程，实现术中实时人工智能影像分析加速，下图 6 为 HiPU 设计框图及其特性。HiPU 工作频率为 233MHz，其峰值算力为 268Gops，卷积效率平均在 80%以上，可有效的对于采集到的医疗影像进行预处理，减轻后端实时导航算法的分析负担。

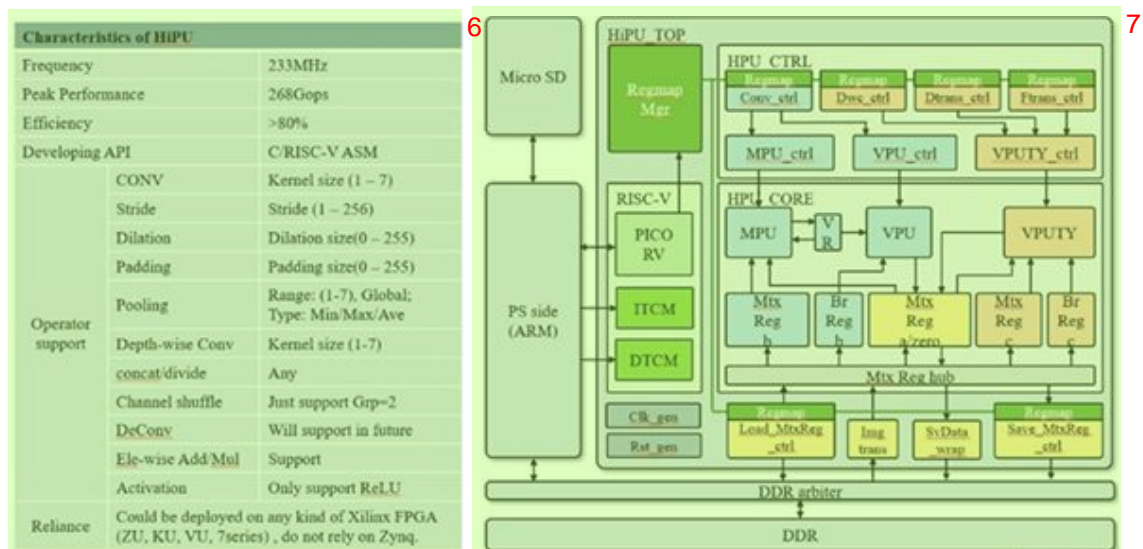


图 6 HiPU 的结构框图与特性

(2) 基于多模态深度学习算法的术中实时手术内容评估模块¹

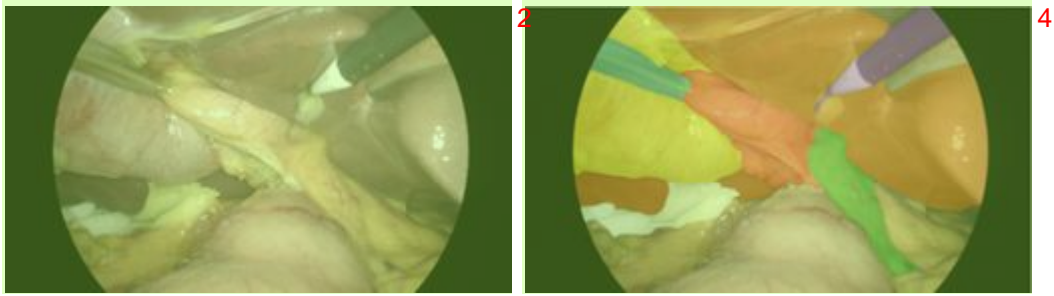


图 7 微创内镜实时影像图³

图 8 微创内镜实时影像分析像图⁵

平台构建了基于术前影像先验信息的实时术中多模态语义分割模型及术中影像记录与分析加速硬件系统，评估切除区域组织脏器实时相对位置，保证肿瘤组织切缘阴性的同时保障荷瘤区域完整性切除，以最大程度保障残余肝功能。如图 7 所示为通过微创手术内镜影像记录分析设备，采集到的微创内镜实时影像图，图 8 所示为微创内镜实时影像分析像图，可见术中实时手术内容识别辅助系统可对于手术内容进行实时精确划分。⁶

平台建设的多中心高精度术中影像分析数据库，为手术影像识别分析技术提供优质数据资源保障，提升术中影像识别算法的效率与准确率。进一步，为更好满足术中实时辅助需要，将在院内搭建术中智能数据实时分析加速平台，使用定制化加速硬件装置，为多类临床术中数据分析与应用任务提供高算力、低延迟保障。语义分割处理后的术中影像视频也将回传至手术室屏幕，实现去除术中电刀、超声刀等器械产生的噪影、对重要解剖脏器的边界识别、术中风险等级评估及手术操作指导等术中辅助功能，提升手术决策准确度。为了更好地减少手术随附损伤，平台建立术中可交互的高精度 AR 可视脏器模型，将手术切除部位在 AR 中同步显示，更好地辅助医生探查血管神经等位置走向。⁷

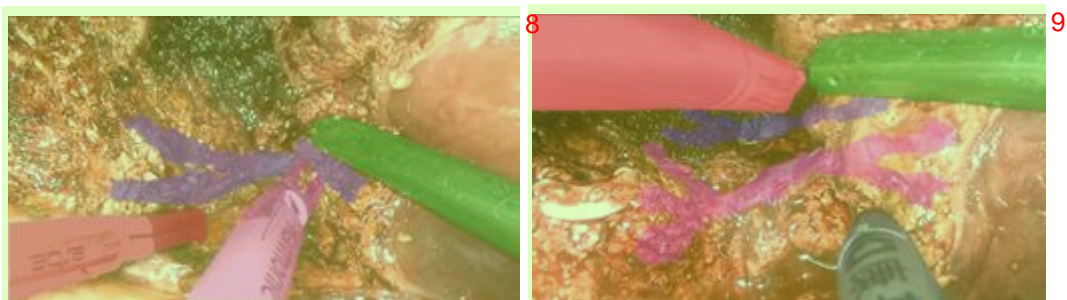


图 9 术中血管及器械智能识别¹⁰

结合基于标准化手术流程及突发状况处理流程的术中影像流程标注数据集¹¹

的实时术中进程识别与应急状况探查方法，明确手术整体流程，评估潜在重要血管损伤风险，有效减少术中并发症的发生；同时准备应急预案，如出现不可避免的术中血管损伤后处理办法，最大程度上减少相关并发症，尽快明确出血位置的同时利用现有手段快速止血，避免延长手术时间，减少对患者的损伤。如图 9 所示为复杂微创术中血管及器械智能识别结果图，可见实时术中进程识别与应急状况探查方法可对于手术潜在损伤进行有效探查。

术中空气栓塞指手术过程中气体进入静脉或动脉系统，可引起低氧血症、高碳酸血症，严重时会导致肺动脉栓塞、心衰等并发症，最佳治疗方式是迅速而有效的重要生命功能的支持和保护。为了避免此类并发症在术中我们需要将肝静脉更精细地解剖，防止进一步损伤，同时对于术中出现的静脉破口及时缝合、凝闭，隔绝血液系统与气腹的长间接接触。因此人工智能监管下可辅助提示术者在有需要暴露血管的情况出现时可适当地降低气腹压力，给予正压通气，并维持一定中心静脉压，术中可定时检查血气指标。

(3) 基于强化学习和小样本监督学习的术中影像智能增强模块

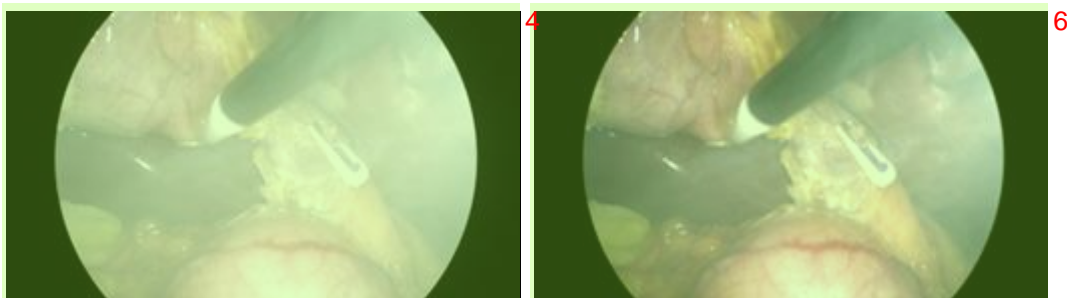


图 10 浓雾场景下内窥镜影像图

图 11 内窥镜影像自动去雾结果图像

在腹腔镜手术中无烟可视化是一个首要问题，烟雾的产生会降低术中医生的可视化程度，导致医生无法对患者异常状况进行及时处理，同时也导致术中影像分析算法在深度估计、语义分割和组织及工具定位等方面的性能不佳。目前腹腔镜主要利用疏散技术排烟等物理方式解决术中烟雾问题，这种方式需要对于现有腹腔镜设备进行额外改造。本平台研发出基于强化学习和小样本监督学习的术中影像智能增强模块，以纯算法的方式，实现了术中腹腔镜影像的实时自动去雾，使烟雾不再影响微创术中医生的视野。如图 10 所示为浓雾场景下内窥镜影像图，图 11 所示为在术中影像智能增强系统下，内窥镜影像实时自动去雾结果图像，可见术中影像智能增强模块可对内窥镜影像进行有效去雾。

同时该系统利用强化学习以及视频间影像的上下文关联性学习,实现了对于腹腔镜血污的自动视觉消除。在患者突发出血模糊镜头的状况下,依然可以通过算法对术中突发的血污画面进行视觉消除,实现自动去血污效果。通过减少清洗镜头的时间,为手术主刀医生争取更多时间处理术中突发事件,为患者救治提供有力基础保障。

(4) 双通道磁锚定荧光专用腹腔镜设备²

平台已研制了一套术中肿瘤病灶定位导航系统,实现可见光信号与荧光信号同时激发和采集的双通道磁锚定荧光专用腹腔镜,该设备从开放式荧光手术导航系统到磁锚定内置镜头和磁锚定荧光专用腹腔镜再到双通道磁锚定荧光专用腹腔镜,逐步更新迭代完成。通过将荧光成像技术引入微创术中定位导航领域,研制磁锚定荧光专用腹腔镜,在保证腹腔镜微创性及操作性的基础上,实现病灶定位的精确性,通过肝切除术彻底清除病灶的目标。

1) 开放式荧光手术导航系统的研制⁴

荧光成像的核心原理是荧光的激发与采集,即荧光手术导航系统主要包含激发部分与采集部分,二者的合理整合及功能实现将决定研制系统的有效性。如图12所示,荧光手术导航系统具体由手持式荧光探头和显示模块组成,其中手持式荧光探头中包括激发组件、采集组件、ABS壳体及亚克力遮挡片。扩束镜为圆柱形铜铁合金包裹的组合透镜,具有自动白平衡、曝光、自动连接恢复及全屏缩放等显示功能;整体设备符合人体工学设计,便于手持式操作。

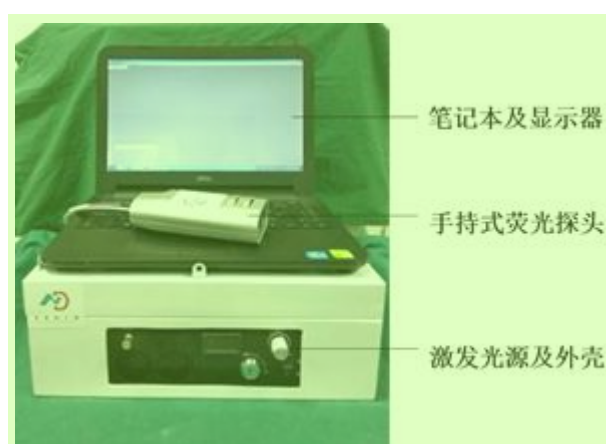

图 12 开放式荧光手术导航系统实物图⁷

2) 磁锚定内置镜头和磁锚定荧光专用腹腔镜系统开发¹

开放式荧光手术导航系统可以实现肿瘤病灶的有效定位，适用于开腹手术。²借助磁锚定技术，联合荧光成像技术，解决传统腹腔镜及单孔腹腔镜切口多、微创性与操作性难以统一的问题，同时自研一套磁锚定荧光专用腹腔镜，如下图 13 所示，以实现减戳卡荧光手术导航。磁锚定荧光专用腹腔镜的核心为磁锚定内置镜头，其作用类似手持式荧光探头作用，同时具有荧光信号的激发与采集功能。而且，其适用于减戳卡手术的模块化设计，体积小、质量轻，在外磁单元的配合下实现移动式腹腔脏器的扫描与观察，更有效地协助手术规划。




图 13 磁锚定荧光专用腹腔镜实物⁴

3) 双通道磁锚定荧光专用腹腔镜的研制⁵

项目研制的磁锚定荧光专用腹腔镜是首个可通过 10mm 传统腹腔镜戳卡的磁锚定荧光腹腔镜，动物实验表明能够进行肿瘤病灶的定位。在明确肿瘤位置的基础之上，要想进行肝切除术，还需要辨别肿瘤病灶与周围正常组织的关系，需额外引入常规彩色成像。项目研制的信号激发与采集的双通道化技术，在磁锚定荧光专用腹腔镜的基础上，引入常规彩色成像激发光源及信号采集模块，实现可见光与荧光信号的同时采集与显示，更便于指导与规划手术。⁶

结合前期磁锚定荧光专用腹腔镜中原模块，在完成双通道磁锚定内置镜头、分光模块的基础上组装双通道磁锚定荧光专用腹腔镜，如图 14 所示。通过吖啶菁绿标准溶液初步测试双通道磁锚定荧光专用腹腔镜进行荧光信号的识别、分光的可行性及有效性。⁷

结果表明其能够同时识别荧光信号及其周围的可见光信号，但也存在一些不足之处，如荧光成像图像不在视野中心、不论是荧光成像还是可见光成像图像较⁸

暗等。接下来将购买高精度传像束组件和分光模块进行设备改进，以提高以上不¹足，对比不同规格的传像束参数来选取最佳传像束参数，以提高荧光信号亮度，改善出现的可见光及荧光信号视野中心导航问题。




图 14 双通道磁锚定荧光专用腹腔镜实物图³

为使系统具有整体化设计，便于手术室等环境的移动，对系统各模块、组件⁴进行布局，设计了如图 15 所示的台车，能够有效置入光源模块、数据处理中心等。按照台车设计，完成加工，同时置入光源、数据处理中心、显示器等，制造优化后的双通道磁锚定荧光专用腹腔镜，如图 16 所示，双通道磁锚定内置镜头位于腹壁模型内侧。

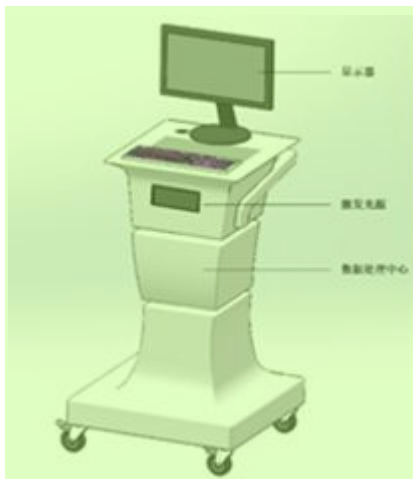


图 15 台车设计模拟图⁶



图 16 双通道微型磁锚定荧光腹腔镜实物⁸

4) 临床验证⁹

临床验证主要是验证荧光手术导航系统在临床中的实际作用，采用临床肝切¹⁰除病例探索所制开放式荧光手术导航系统肿瘤病灶定位及划定切肝线的有效性。

研究经西安交通大学第一附属医院伦理委员会审批, 仔细筛选病例后取得患者及家属的知情同意, 并签署相关知情同意书。

① 肝癌病灶定位临床验证

病例资料: 患者魏某, 男, 43 岁。以“乙肝病史 20 年, 体检发现肝占 2w”之主诉入院, MRI 普美显增强提示肝右叶肝占位性病变, 考虑肝癌, 初步诊断“原发性肝癌”, 行腹腔镜手术治疗。

手术流程如下: a.术前 3d 外周静脉注射 ICG 溶液, 行肝功尺检查; b.常规麻醉, 消毒铺巾, 肝脏离体后取出; c.开启荧光手术导航系统, 设定参数; d.手持式荧光探头指向肝脏表面, 观察系统显示屏显示内容; e.取得肝脏离体标本; f.通过显示屏观察到脏离体标本上肿瘤病灶情况; g.对肝脏离体标本进行组织学 HE 染色; h.处理腹腔, 止血, 关腹术毕; i.术后病例结果验证, 如图 17 所示, 图中显示癌细胞呈片排列, 病理诊断为高分化肝细胞肝癌, 与荧光信号为全荧光信号相吻。




图 17 荧光手术导航系统临床肝癌病灶定位成像

(a) 离体肝脏大体观; (b) 离体肝脏荧光成像; (c) HE 染色。

② 切肝线识别临床验证

病例资料: 患者杨某, 男, 67 岁, 以“腹胀伴发热 6d”之主诉入院, MRI 提示肝右叶近肝门处占位性病变, 肝门区胆管及右肝管异常改变, 性质多考虑肝脏恶性肿瘤, 初步诊断为“肝占位”, 行右半肝切除术, 术后诊断“肝门部胆管癌”。

手术流程如下: a.常规麻醉, 消毒铺巾, 逆行联合右半肝+全尾状叶切除、肝门部胆管切除及胆肠吻合术; b.游离韧带, 显露肝叶, 辨别及分离出门静脉左支; c.开启荧光手术导航系统, 设定参数; d.由门静脉左支注入备用 ICG 溶液 1ml, 手持式荧光探头指向肝脏表面, 观察系统显示屏显示内容; e.显示屏非常直观、

清楚地看到左内叶及左外叶清晰显影，右半肝未显影；f.如图 18 所示，术中结果¹表明，开放式荧光手术导航系统划定切肝线，与门脉预阻断形成的缺血带相吻合，可有效对切肝线进行定位，进而实现引导激光进行精准肝切除。

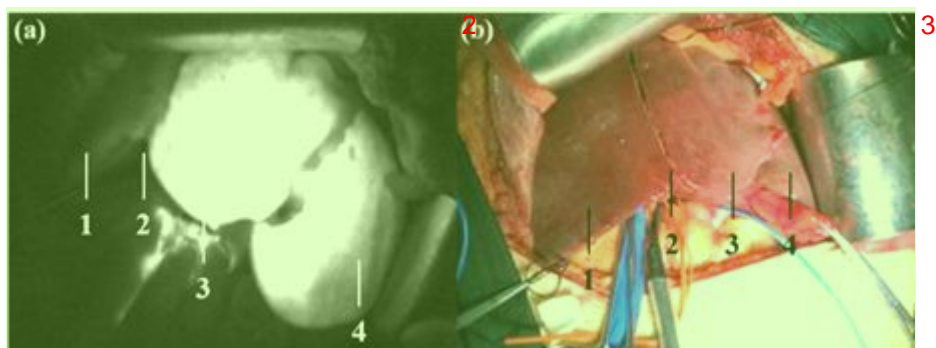


图 18 荧光手术导航系统临床肝切除切肝线识别成像⁴

通过临床病例病灶的定位与切肝线划定等模拟实验，表明所制双通道磁锚定⁵荧光专用腹腔镜能够通过 10mm 置入腹腔并稳定锚定于腹壁并移动。同时，通过临床双通道磁锚定荧光专用腹腔镜辅助下成功实现肝癌病灶精准定位、划定切肝线，进而实现引导激光进行精准肝切除，证明荧光手术导航系统的实际有效性。

(5) 术中荧光成像结合 AR 明确手术切除路径⁶




图 19 术中荧光腹腔镜功能性解剖区域显像系统⁹

术中结合超声穿刺定位肿瘤营养血管后染色，进行功能性解剖区域正染、反¹⁰染，利用肿瘤特异的功能性荧光成像技术在术中实时优化术者决策，术中荧光腹腔镜功能性解剖区域显像系统如图 19 所示，其可有效地明确手术切除边界，助力临床改进精准术式。




图 20 基于增强现实技术的术中荧光腹腔镜三维影像显像系统 2

将 AR 技术与术前影像三维重建的 AR 信息融合创新软硬件系统设计，匹配术中 AR 三维影像与术中实时影像的非同质信息融合定位与配准技术，整体系统效果如图 20 所示。利用术前规划好的解剖基准点作为参照物，实时地将手术患者脉管系统投影于 AR 眼镜中，术中根据抬头唤醒实时明确手术重要解剖部位，做到术中肝段界限可视化，更直观地呈现目标肝段的分界线，尤其是对合并肝硬化的肝缺血首先进行校正，有效减少术中血管神经损伤，避免医源性二次伤害；此外，还可实时提示是否偏移术前规划路径，做到路径矫正与实时分析，优化手术流程，造福每一位手术的患者。

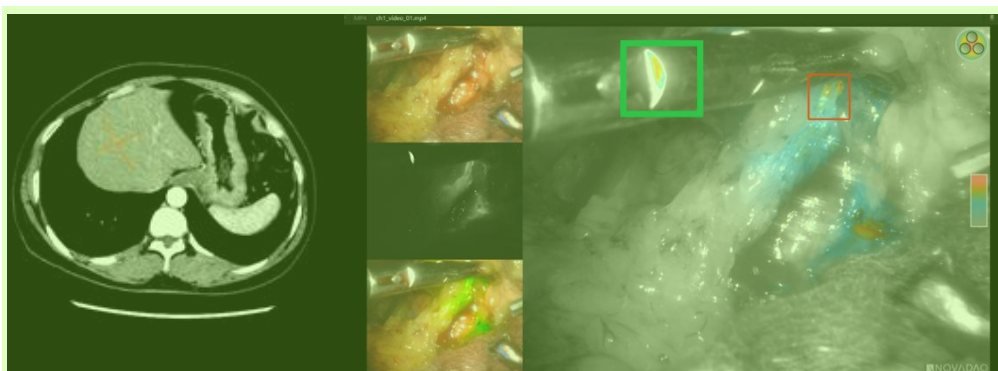


图 21 荧光成像下智能识别微小转移灶 5

功能性荧光成像技术也可助力术者在术中发现肿瘤多发病灶，结合深度学习目标检测算法分析后可有效地发现肉眼难以察觉到的微小转移灶，荧光成像下人工智能微小转移灶识别效果如图 21 所示，可有效实现术中肿瘤病灶精准切除。

(6) 术中微创图文记录模块 1

医疗文书作为医生进行临床活动主要依据，外科手术记录是临床治疗中最为重要的医疗文书之一，如图 22 所示，目前手术文书记录大部分由下级医师手术后将信息录入至相关文书写作系统中，但其存在较多缺点，非主刀医师执笔、记录内容不精确、字叙述不明且同质化严重、复制粘贴现象严重。

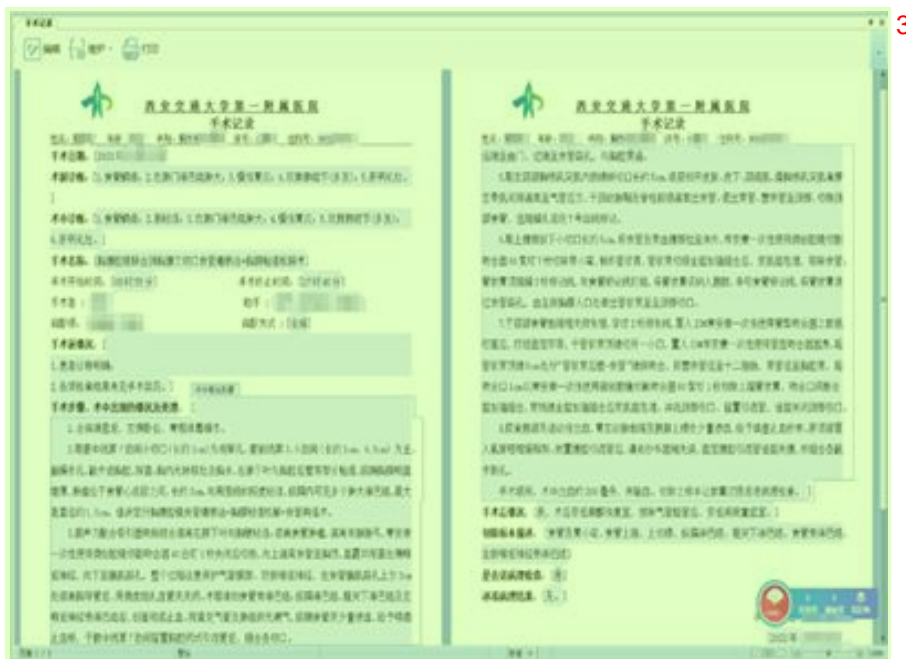

图 22 现有文字版外科手术记录 4

同时，现有很多诊断项目，如临床病理学诊断、影像学检查、内窥镜检查等，早已采用了图文报告的形式且有其规范要求。针对于现有纯文字外科手术记录存在的各类问题，平台构建基于外科手术影像记录设备的微创图文手术记录系统，构建出如图 23 所示的图文报告，直接反映患者的病变程度及术中处理情况，为患者后续治疗提供诊断依据，亦能作为术后医患沟通的主要凭证，减少医患矛盾，减少医疗资源的重复与浪费。除此之外，微创图文手术记录能够将专业医生的临床经验及手术流程步骤等便捷地传播给其他年轻医生，加强医学生培养。

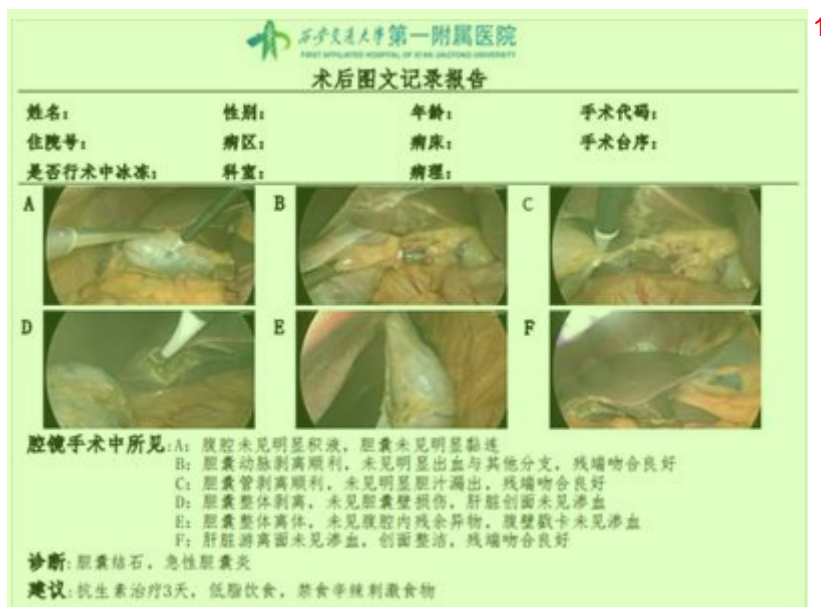

图 23 图文报告模块生成的图文外科手术记录²

平台构建出的微创腹腔镜系统的图文记录模块，可以按照既定手术流程，根据³外科手术影像记录设备所记录的术中影像，帮助主刀医生快速生成微创图文手术报告，系统生成的图文手术记录如图 23 所示；未来项目将以现有海量医疗文书作为数据基础，融合知识图谱医疗信息抽取算法，设计图文外科手术记录自动生成算法，进一步简化临床医生图文报告写作流程，赋能智能化精准医疗目标。



图 24 术腹腔镜影像采集装置⁵

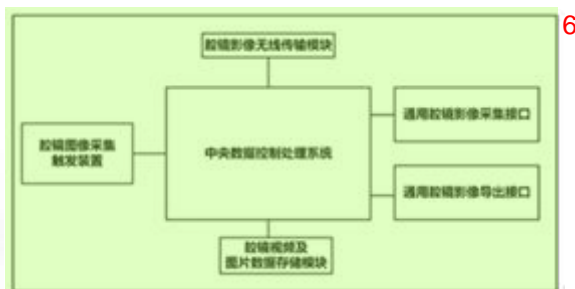


图 25 术腹腔镜图像采集装置结构示意图⁷

外科手术影像记录设备，如图 24、25 所示，其上通配接口方案可以适配现⁸有主流器械厂家的腹腔镜影像输出模式，实现不同厂家、不同输出端口的腹腔镜影像采集；设备本身带有无线传输模块，实现无线术中影像的传输和储存，并与微创图文手术记录系统相连，以方便图文手术报告生成。将构建带有辅助分析功能的术中影像分析装置，对于采集到的术中影像进行分析，进一步为微创术中医生提

供人工智能医疗辅助。¹

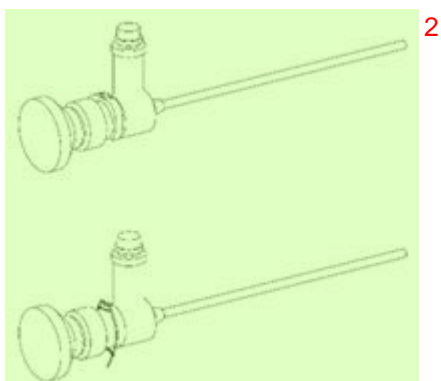


图 26 组装后术中影像采集按钮组件³

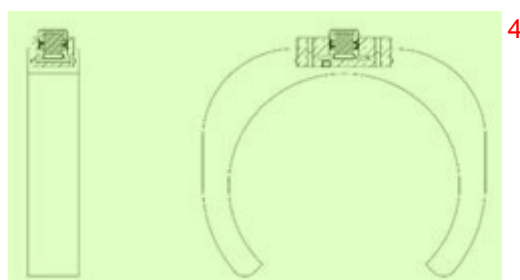


图 27 管套式术中影像采集按钮组件⁵

外科手术影像记录设备配套有术中影像采集按钮组件，如图 26、27 所示，⁶ 以方便外科手术影像记录设备进行术中影像关键帧采集，术前医生将按钮组件安装在腔镜影像设备中，术中医生通过按压，实现术中影像关键帧的及时采集，避免术中医生需要走到影像采集装置前进行术中影像采集，方便术中医生影像采集操作。

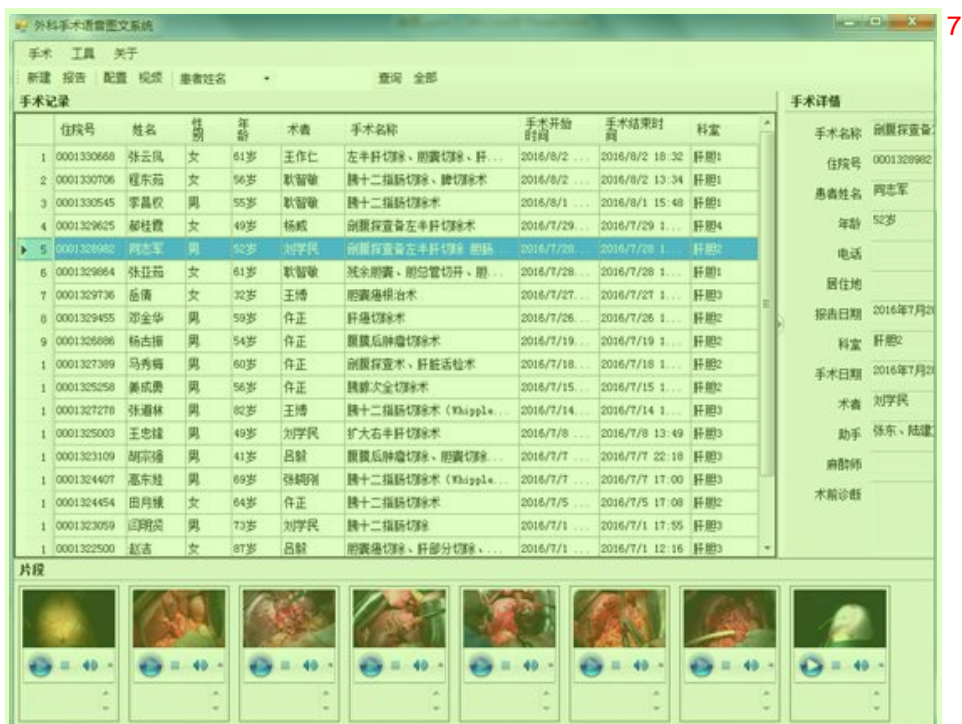

图 28 微创外科图文记录系统⁸

平台研发的微创图文手术记录系统，其直接与医疗 HIS 系统、外科手术影像⁹ 记录设备无线相连，自动将患者基本信息、采集术中影像接入系统，减少医疗文

书书写过程中对于既有信息的繁琐复制粘贴工作。微创图文手术记录系统如图 28 所示，在手术记录增加术中图像相关内容，对纯文字手术记录进行数字化赋能，使其更为生动具体，为术后及愈后阶段医生决策提供更为全面的患者信息。

3. 建立智能化多功能人才培养体系²

通过前期工作所建立的术前精准定位导航系统，术中真实影像识别分割系统，结合新型的术后图文记录报告，可为临床人才培养提供更加生动真实的临床案例，将相关病例信息内置于虚拟现实 VR 课堂中，通过实时交互的教学模式提升医学生对术中重要部位辨识能力，更好地加强学生对于手术的实践理解，缓解医疗资源紧缺问题的同时为青年医师培训与医学生了解前沿手术内容建立虚拟的仿真教学平台。通过对不同手术的关键帧内容进行文字描述后生成匹配的图文模块，明确手术关键流程步骤，同时将手术中的重要事件及处理办法进行单独关键帧的描述，如意外损伤血管后的处理办法，让学员们明确在不同出血场景下应选择哪些对应有效地处理解决办法。

所搭建的人才培养体系主要由手术规范化流程构建与线上教学平台搭建两部分内容组成。首先对于手术规范化流程进行构建后，搭建起基于术中真实影像、标准化、可定量评价学生学习质量的线上教学平台。手术规范化流程培养可以降低因为流程不明确导致的手术恶性事件发生，同时通过课前视频预习、课上教师根据实时真实术中影像的讲解、配合教师标注的真实术中影像脏器识别图像，更好地促进学生对于相关知识系统化吸收；通过课后选择判断题、真实影像脏器识别关键点标注平台，自动定量生成学生学习效果报告，督促学生进行自查，同时给出学习薄弱的针对性学习建议，为临床医学生提供他们所需要优质资源，进一步加强临床医学生的学习效率。形成一个基于术中真实影像的流程化、规范化、自动化、评价可量化的手术教学新模式，促进临床医学生对于手术的掌握，提升临床医学生学习趣味程度，以真实影像作为学习依托，强化教学效果。

（六）项目技术基础⁵

1. 荧光成像与磁外科技术相结合，平台自主研发了适用于微创化术中导航的双通道磁锚定荧光专用腹腔镜设备，已完成临床验证。该设备既能定位肿瘤病灶，又能明确病灶与周围正常组织的位置关系，便于进行荧光成像引导下的精准肝切除。之后需对该设备参数不断优化迭代，并与影像智能技术相融合，使其达

到最佳导航效果，同时将其推广至多个应用场景。¹

2. 平台为每位患者定制个性化手术的入路规划。通过 AR 设备在术前不断²进行手术路径与切除方式规划，降低术者对于既往经验的依赖。功能性人工智能影像组学分析，明确潜在的血管癌栓、微血管浸润、术中重要组织脏器粘连和腹壁侵犯转移等特殊事件的发生，有效避免术中血管损伤等并发症。之后拟进行 AR 智能化术前分析系统推广，为更多医院进行服务。

3. 平台利用微创手术图文报告生成系统，通过现有微创外科手术的图文影像采集设备，结合微创术后图文记录生成模块，形成体系化的微创术中影像记录与分析系统，打造定制化图文报告，有效提高医患沟通效率与信任度。将有效为基层医院提供远程医疗会诊服务，实现优质医疗资源下沉。

4. 平台构建了根据术前影像先验信息的实时术中多模态语义分割模型及术中影像记录与分析加速硬件模块，利用自建的术中影像数据集并训练高精度的图像识别分割算法，术中数据分析后回传术中影像视频至手术室屏幕，实现术中重要解剖脏器的识别。未来将匹配术前建立的高精度 AR 模型，将术中已切除部位在 AR 内容中实时更新，利用标准化手术流程及突发状况处理流程进行术中手术路径规划导航并做到特殊事件预警。

5. 平台通过术中影像记录系统，结合自研的强化学习和小样本监督学习的术中影像智能增强方法，可以对术中图像算法自动去雾和对于腹腔镜血污的自动视觉消除，实现自动去血雾效果，避免血雾影响术中医生的视野，为患者救治提供有力基础保障。

6. 依托平台构建出基于影像资料的智能化多功能人才培养平台方案。建立规范化、标准化手术流程，并提供术中真实影像视频资料和本平台独有的智能化高仿真全脏器手术训练系统，帮助医学生从各维度进行基本功训练与高级技巧训练，了解目前最前沿的手术方式；辅助青年医生锻炼手术操作，缩短复杂手术的学习时间。后期需将方案落实并应用于人才培养实践中。

（七）建设周期与进度安排¹

| 建设周期 | 时间 | 进度安排 |
|------|-----------------------|---|
| 一 | 2023.01.01—2023.5.31 | 购置软硬件设备，建立健全运行管理的体制机制，完成临床前基础研究工作及软硬件平台测试，完善伦理申报等工作。 |
| 二 | 2023.06.01—2024.6.31 | 手术智能导航平台在临床外科手术术前规划、术中导航等方面取得一系列进展，根据临床实际应用反馈做到硬件迭代，优化算法，扩大临床应用场景及应用规模，并在智能化导航医疗装备设备研发与临床应用方面取得高水平标志性成果，专利申报。 |
| 三 | 2024.07.01—2025.7.31 | 解决医疗领域关键核心技术难题，参与学术交流，在全国范围内进行平台成果转化推广会，进一步扩大临床应用场景，为更多的医院提供规模化的服务，推动产学研融合，发表高质量文章。 |
| 四 | 2025.08.01—2025.12.31 | 推广相关产品，建立行业标准，带动智能化手术导航产业高端化发展，完成项目考核指标，准备结题验收材料。 |

（八）总投资及资金来源³

项目总投资 2500 万，主要包括固定资产投资 2000 万，自有资金 500 万，其他资金 0 万。

（九）建设条件落实情况⁵

1. 科研基础⁶

依托中心现有基础，平台充分利用交通大学医工交叉的优势以及与国内著名人工智能专家合作，20 多年来坚持持续原始自主创新，开展机理、材料、模拟、设计、加工、实验、试用等系统化磁相关医疗器械装置的研发，形成了多项原创

技术，部分成果实现了转化，2017年图文手术记录技术获得转让费106万，2019¹年磁性吻合器技术获得转让费300万，2021年多个磁相关技术共获得转让费1000万。团队技术创新能力在本领域遥遥领先，科研实力雄厚。

2. 科研条件²

(1) 科研用房³

平台依托陕西省再生医学与外科工程研究中心组建，学校及医院已投入大量的经费进行建设，面积约2300平方米，其中实验室面积约2000平方米，办公面积约220平方米，资料室约80平方米，物理空间基本可以满足平台建设的要求。⁴

(2) 仪器设备⁵

现有分子生物学基础实验室、动物手术室（普通手术室、杂交手术室）、磁⁶外科研究室、生物工程研究室、医用高分子材料研究室、计算机辅助模拟室、激光研究室、人工智能与医疗机器人研究室等。科研仪器设备包括全自动快速微生物质谱检测系统、超速分选流式细胞仪、酶标测试仪、二代测序系统、染色体自动扫描分析系统、激光共聚焦显微镜、全自动核酸分离纯化及加样系统、小动物磁共振、磁场测量仪等大型仪器，能够满足校内外生命、医学、药学、化学、材料、机械等交叉学科科研需求。

(3) 配套设施⁷

1) 实验动物中心⁸

西安交通大学实验动物中心是目前国内高校单体最大的综合性实验动物设施⁹。平台可饲养啮齿类、家兔、犬、猪、山羊、绵羊、非人灵长类动物和一些特殊动物，配备动物实验所需先进仪器设备，符合国际标准的药物非临床研究质量管理规范(GLP)。建成后将申请CMA、CNAS、AAALAC评估和认证，满足生物医学研究和教学需要，支撑西安交通大学医、工、理和文等多学科交叉融合。

2) 分析测试中心¹⁰

西安交通大学分析测试共享中心建筑面积3400平方米，首期投入设备购置¹¹经费7600万元，已购置28套大型仪器设备，包括透射电镜、扫描电镜、核磁共振波谱仪、高分辨质谱仪、显微红外光谱仪、激光拉曼光谱仪、电感耦合等离子体质谱仪、X射线光电子能谱仪、X射线荧光光谱仪、X射线衍射仪等大型分析测试设备。为开展高水平的教学科研工作及培养引进高水平的人才提供了有力支

持。¹

3) 高性能计算平台²

西安交通大学高性能计算平台总体计算规模达 230 万亿次, 位居西部高校首位、全国高校前列, 能够为全校师生提供专业、一体化、方便快捷的高性能计算服务。平台可提供 CPU 节点、GPU 节点、管理节点、登录节点、存储系统。软件操作系统为 CentOS 6.6 64bit, 拥有 MATLAB、lammps、vasp、gaussian、amber16、gromacs、R、python、cp2k 等应用软件资源。可为研究中的大数据处理与分析提供可靠、充足的资源。³

4) 高端装备研究院⁴

西安交通大学高端装备研究院依托机械工程学院组建成立, 以“四个面向”⁵为指引, 大力推进学科交叉融合, 聚焦航空航天、机器人与智能系统、设计科学与基础部件、医工交叉、先进制造、精密工程、装备智能诊断与控制、新能源装备与质量工程等领域开展研究, 是自主研发, 全力打造高端装备、智能制造领域核心技术攻关和创新人才培养高地。可为本项目的顺利实施提供强有力的技术支持。

除以上校内研究机构和平台支持外, 平台还长期与校外西北有色金属研究院、⁶西部超导材料科技股份有限公司、西安赛德欧医疗研究院有限公司等科研院所及企业保持良好的合作关系, 加速成果快速转化, 推进产业化进程。

5) 平台建设其他必要配套设施⁷

本平台所在地给排水、供电、供热、电信及通讯等公共设施社会依托条件比较完备, 利用依托单位整体资源进行校内改建, 能够充分满足项目建设需要。⁸

① 原材料供应条件⁹

有学校和医院招标采购部门强有力保障, 拥有相对固定且长期合作的伙伴,¹⁰能保证科研所用的原材料质量和快速供货。

② 供水排水条件¹¹

西安交通大学雁塔校区现有供水水源来自西安市自来水供水管网, 学校有¹²DN80~DN200 的市政进水口 13 个, 日均供水 2 万 m³, 实现了全面积覆盖供水。共有二次供水水库 17 座, 累计库容 13630 m³, 二次供水水泵总台数 73 台, 全部实现了变频恒压供水。现有供水能力有富余, 可满足平台的用水需要。

学校现有排水设施齐全，实行雨、污分流制，经学校污水处理设施处理后排入附近的市政污水管网。现有排水设施能够满足本平台的需要。

③ 供电条件²

现有供电能力有富余，可以满足平台科研工作的需要。医院为双路供电，一路停电，即可启动另一路供电系统，保障医疗和科研用电安全。

④ 外部协作条件⁴

本平台所在的西安市位于陕西省中部，是陕西省委、省政府所在地，是全省政治、经济、文化中心。西安市是我国重要的科研、高等教育、国防科技工业和高新技术产业基地，是新欧亚大陆桥中国段陇海兰新地带最大的中心城市，是我国科研教育和高新技术产业的重要基地。西安的综合科技实力位居全国大城市前列，具有仅次于北京、上海的综合科技实力和智力机构。西安的大专院校、科研院所、技术开发机构和专家学者、专业人员众多，拥有一批达到国际水平的开放型实验室和国内一流的试验和检测设备，一些尖端技术在国内处于领先地位。工程建设和科研所需外部协作条件均已具备。

（十）投资完成情况和工程形象进度⁶

前期平台建设日常运行等已累计投资 2500 万元，初具规模并在业内具有一定影响力，部分成果已实现转化。

（十一）效益分析⁸

党的二十大报告将“健康中国”作为我国 2035 年发展总体目标的一个重要方面，提出“把保障人民健康放在优先发展的战略位置，完善人民健康促进政策”，并对“推进健康中国建设”作出全面部署。从优化人口发展战略，到实施积极应对人口老龄化国家战略；从深化医药卫生体制改革，到重视心理健康和精神卫生，都充分体现了对人民健康的高度重视，充分彰显了以人民为中心的发展思想。本平台建设具有广泛的临床应用前景，符合国家层面健康中国战略与医院信息化建设与管理方针，利用人工智能技术赋能，为患者提供个性化定制手术策略，做到术前有效规划、术中智能导航，符合 21 世纪精准医疗的要求，有效节约医疗资源，降低社会负担。

在科技创新层面，本平台聚焦医疗健康领域关键核心技术难题，创造性地将

智能化手段结合手术导航中，促进临床医学技术革新，健全医学人才培养体系，¹推动医疗行业高端化发展，引领行业发展，有效地服务临床的同时为患者提供更优质的医疗服务，为所有患者的生命健康保驾护航。从社会效益上来看，通过智能化导航平台，有效地为临床医生提供辅助决策，优化手术方案，最大限度地利用智能化资源对现有的患者信息整合分析再利用，有效缓解当前医疗资源总体不足，配置不均衡，更好地为更多的患者群体提供精准化治疗方案，可以带来较好的社会效益及间接的经济效益。

（十二）资金需求²

申请资金 500 万，主要在现有基于手持式荧光内镜与磁锚定手术设备的微创³术中导航系统的基础上，提升微创术中导航系统对术前患者信息的利用效率，构建集术前、术中信息于一体的智能化诊疗平台。资金用于相关分析设备、诊疗材料购置，关键技术研发，成品导航系统构建与专家咨询费，安放使用装备专用医疗场所建设，燃料动力费以及技术交流费，临时人员劳务费，出版/文献/信息传播/知识产权事务费等。

依据国家发展改革委《战略性新兴产业重点产品和服务指导目录》（发改投资（2017）1 号）要求，申请的基于微创术中导航的全流程智能化诊疗开发平台⁴建设项目符合文件中**先进治疗设备及服务板块**中有关于术中定位、术中成像、术中治疗、影像导航等手术治疗设备及其一体化信息系统所支持方向和申报条件相关要求，未获得过中央和省上资金支持。

1. 项目经费预算:¹

| 计划新增投资支出情况（万元） ² | | | |
|-----------------------------|--------|--------|--|
| 支出科目 | 新增投资总额 | 省级资助经费 | 说明 |
| 一、直接费用 | 465.0 | 465.0 | 主要用于以下内容 |
| 1、设备费 | 350.0 | 350.0 | 用于购置相关设备费 |
| (1) 购置设备费 | 350.0 | 350.00 | 用于购置仿真测试模型、术中导航系统构建、全流程数据处理平台构建、算法优化计算硬件购买 |
| (2) 试制设备费 | 0 | 0. | 无 |
| (3) 设备改造与租赁 | 0 | 0 | 无 |
| 2、材料费 | 90.0 | 90.0 | 数据分析及中控子系统、术中磁锚定位及导航系统、荧光腔镜采集系统所需耗材及材料、实验动物等 |
| 3、测试化验加工费 | 5.0 | 5.0 | 动物实验验证安全性、设备电气安全性测试 |
| 4、燃料动力费 | 0.0 | 0.0 | 项目单位承担此项费用 |
| 5、差旅费 | 3. | 3.00 | 测试、在外单位应用推广、申报注册等 |
| 6、会议费 | 1.0 | 1.0 | 参加学术交流、产品推介等 |
| 7、国际合作与交流费 | 0 | 0 | 无 |
| 8、信息费（出版/文献/信息传播/知识产权事务费等） | 10.0 | 10.0 | 文献查新、专利、版面费、媒体宣传等 |
| 9、专家咨询费 | 2.0 | 2.0 | 研发过程中瓶颈问题咨询等 |
| 10、劳务费 | 3.0 | 3.0 | 支付参与项目的研究生或临时聘用人员薪酬 |
| 11、其他支出 | 1.0 | 1.0 | 资料打印、设备邮寄费等 |
| 二、间接费用 | 35.0 | 35.0 | 管理费、绩效支出 |
| 1、管理费 | 30.0 | 30.0 | 项目申请单位的项目管理费 |
| 2、绩效支出 | 5.0 | 5.0 | 对项目组成员的奖励 |
| 合计 | 500.0 | 500.0 | 项目申请经费总计 |

2. 平台建设费用预算说明清单：¹

(1) 设备费 - 350 万元：²

1) 专用仿真人体模型 2 套，单价 30 万，用于验证术中导航系统的安全性和有效性，总计 60 万元³

与提升项目的关系：主要用于评价仪器监测的安全性和有效性。主要组成部分：⁴
① 胸部模 ② 肺部模 ③ 腹部模 ④ 肝胆模

与项目承担单位基础支撑条件的关系：自完成术中导航系统研发后，需要在仿真人体体模中评价微创导航系统的安全性和有效性，目前承研单位还未有此类模体，为了满足完成项目需求，需购买仿真人体体模一套。⁵

价格构成依据：见下表⁶

| 仪器 | 品牌及公司名称 | 价格（万元） | 电话 |
|--------|------------------|--------|-------------|
| 仿真人体模型 | PTW, 北京华制莹有限公司 | 30.0 | 18991226032 |
| | GIRS, 北京华光普泰有限公司 | 35.0 | 13552203130 |
| | ATOM, 上海生源有限公司 | 40.0 | 13572527385 |

⁷

2) 微创术中导航规划工作站 2 套，单价 153198.0 元，用于三维图像重建、微创术中导航规划与分析，总计 30.6 万元⁸

品牌：戴尔图形工作站/三星高清显示器⁹

型号/规格：K630/三星 U32J590UQC¹⁰

与提升项目的关系：为本项目提供用于术前数据三维建模、术中手术定位及导航算法分析及数据处理的高性能设备。¹¹

与项目承担单位基础支撑条件的关系：微创术中导航中存在大量术前三维影像重建、三维术前影像识别、病灶快速定位、基于知识图谱信息融合和路径规划等运算，且需要对算法进行参数优化等操作，因此对该设备在运算性能、图形处理能力等方面具有较高的技术要求，需购置 2 套，用于利用术前影像数据进行建模、微创术中导航的数据分析工作。¹²

价格构成依据：K630 单台售价 150599.0 元；三星 U32J590UQC 2599.0 元。¹³

3) 购置高仿真微创手术训练系统 2 台，单价 25 万元，共计 50 万元¹⁴

与研制设备的关系：用于术中导航相关微创手术仿真实验，与专用仿真人体模型配合使用，创建模拟微创导航手术环境，并且通过手术训练系统对于影像记录和内置多影像摄像机，优化术中导航系统的使用流程。¹⁵

价格构成依据：根据相应供应商提供的报价预计每台 25 万元，总计 50 万。¹

4) 单价均未超过 10 万元的计算及服务器资源 2 套，共计 44 万元，用于数据配准，三维影像建模重建与线上临床医疗教学平台构建

与提升项目的关系：为本项目提供用于数据配准、三维图像数学物理建模和医疗文书数据分析的计算资源；同时搭建基于术中影像导航的线上临床医疗教学平台。³

与项目承担单位基础支撑条件的关系：项目中存在大量三维重建、数据配准、数学物理建模和医疗文书数据分析等运算，且需要对算法进行参数优化等操作；同时，项目拟构建基于术中导航的临床医疗教学系统，需要相关的网络硬件平台提供服务，因此对该设备在运算性能、影像处理能力、网络传输等方面具有较高的技术要求，需购置 2 套。⁴

价格构成依据：设备费主要用于购置计算资源：服务器/工作站，用于并行计算的 GPU 等，以 9.5 万元 GPU 2 个，以及相应配件及入网安装服务 3 万元，一套 22 万元，共计 44 万元。⁵

5) 购置无线微创术中影像图文采集装置 5 台，单价 4 万元，共计 20 万元⁶

与研制设备的关系：用于对导航相关微创术中影像无线采集收集，快速构建微创术中导航路径数据集。⁷

价格构成依据：根据相应供应商提供的报价预计每台 4 万元，总计 20 万。⁸

6) 购置深度学习计算卡 7 块，单价 67999.0 元，共计 47.6 万元⁹

品牌：NVIDIA¹⁰

型号/规格：NVIDIA Tesla V100 32G¹¹

与提升项目的关系：用于结合术中影像分析的术中实时导航路径规划处理加速，需要 4 块；用于三维术前影像图像预处理过程中深度神经网络的搭建与训练，需要 2 块。拟采购 NVIDIA 英伟达 NVIDIA Tesla V100 32G。¹²

与项目承担单位基础支撑条件的关系：项目拟进行的结合术中影像分析的实时导航路径规划处理加速，以及拟开发的三维术前影像图像预处理方法涉及深度神经网络的搭建与训练，深度学习计算卡必不可少。目前，承研单位还未有相关计算设备。为了满足完成项目需求，提高处理速度，需购买深度学习计算卡 6 块。¹³

7) 购置 AR 医学交互设备 3 套，单价 15 万元，共计 45 万元¹

与提升项目的关系：用于微创术中实时器官三维影像术中实时呈现，及术中²导航规划路径显示及远程术中交互指导。

与项目承担单位基础支撑条件的关系：项目拟进行的术中实时三维器官影像³术中实时呈现，通过基于术前器官三维影像建模与手术路径导航及规划，通过 AR 医学交互设备为术中医生提供可视化的三维导航辅助，增强医生对于患者待手术器官整体情况了解，辅助医生提升术中手术操作精度，预防术中各类并发症，有效保存术中功能性区域，提示肉眼不容易识别的病灶。目前，承研单位还未有相关 AR 设备。为了满足完成项目需求，提高处理速度，需购买 AR 医学交互设备 3 套。

价格构成依据：根据相应供应商提供的报价预计每套 15 万元，总计 45 万。⁴

8) 购置边缘计算加速 FPGA 硬件 3 套，单价 11 万元，共计 33 万元⁵

与提升项目的关系：用于在手术室内对于术中影像视频进行低功耗快速语义⁶分割前处理，因此需要 FPGA 边缘计算加速硬件提升预处理分析效率。

与项目承担单位基础支撑条件的关系：项目拟进行的术中实时术中三维影像⁷导航与关键操作提示系统，首先需要对于采集到的术中影像视频进行语义分割预处理，通过 FPGA 边缘计算加速设备为接下来的术中导航提供足够的术中医疗语义辅助信息，增强智能导航系统对于手术流程情况理解，提升术中导航精度，是手术导航的前置必要性预处理步骤。目前，承研单位还未有相关买边缘计算加速 FPGA 硬件设备。为了满足完成项目需求，提高处理速度，需购买边缘计算加速 FPGA 硬件设备 3 套。

价格构成依据：根据相应供应商提供的报价预计每套 11 万元，总计 33 万。⁸

9) 购置术中磁锚定辅助操作机械臂 1 台，单价 9 万元，共计 9 万元⁹

与项目的关系：用于微创术中磁锚定装置体外移动控制，术前预制术中不同¹⁰阶段体外控制机械臂移动路径后，进行磁锚定辅助移动控制操作。

与项目承担单位基础支撑条件的关系：项目拟进行的术中磁锚定辅助系统对于¹¹术中待手术脏器进行夹持控制，通过磁引导的方式进行控制，同时通过体外辅助操作机械臂精确控制精度，通过磁导航体外辅助的方式，减少术中医生对于待处理脏器的夹持工作，解放微创小孔径、小手术环境下所需手术器械的大小，使

医生在术中有更大的操作空间，更好地处理术中的异常状况。目前，承研单位还
未有相关外部辅助机械操作臂设备。为了满足完成项目需求，通过磁锚定方式更
好地提高术中辅助程度，需购买术中磁锚定辅助操作机械臂一台。

价格构成依据：根据相应供应商提供的报价预计每套 9 万元，总计 9 万。

10) 数据存储模块：预计 9.5 万元

与提升项目的关系：是系统的重要组成部分，用于系统研制过程中的海量数
据存储与数据管理。主要由 NAS 磁盘阵列盒网络存储器文件备份服务器和
NAS 网络存储硬盘构成。

与项目承担单位基础支撑条件的关系：项目拟进行的微创术中导航系统，需
要大量术前医疗影像图像以及多科室不同手术下的医学手术文书资料与影像信
息作为导航系统的训练数据集，以提升术中定位精度、术中导航精度与术中影像
识别的精确程度。目前，承研单位还未有相关大规模数据储存集群设备。为了满
足完成项目需求，存储相关术中、术前及术后全流程数据，需购 NAS 磁盘阵列
文件存储系统。

成本构成与测算依据：

| 器件名称 | 用量 (个) | 单价 (万元) | 总价 (万元) |
|---------------------------|--------|---------|---------|
| NAS 硬盘阵列盒网络存 储器文件备份服务器 | 1 | 2.0 | 2.0 |
| NAS 网络存储硬盘 | 30 | 0.25 | 7.5 |

2. 材料费 - 90 万元

用于项目提升材料以及实验所需耗材等的支出。

| 常用范围 | 耗材名称 | 购置数量 | 计量单位 | 单价/元 | 金额/万元 |
|----------------|-----------------------------|------|------|---------|-------|
| 数据分析及中控 子系统 | Ni-PX1-8238 兆网接口 | 1 | 个 | 18000.0 | 1.8 |
| | NI-PX1-6683 同步脉冲卡 | 1 | 个 | 21000.0 | 2.1 |
| | NI-PX1-8531 可编程控制 器总线接口卡 | 1 | 个 | 10500.0 | 1.05 |
| | NI-PXI-8517 反射式激光器 总线接口卡 | 1 | 个 | 45000.0 | 4.5 |
| | 时序逻辑控制板卡 | 1 | 个 | 9000.0 | 0.9 |

| 常用范围 | 耗材名称 | 购置数量 | 计量单位 | 单价/元 | 金额/万元 |
|-------------|-------------------------|----------------|------|---------|-------|
| | Kintex-7 | | | | |
| 术中磁锚定位及导航系统 | 磁感应线圈 | 300 | 个 | 200.0 | 6.0 |
| | 高精度电容触摸屏 | 5 | 个 | 4200.0 | 2.1 |
| | 耐高温磁铁 | 10 | 个 | 2000.0 | 2.0 |
| | 医用支架 | 50 | 个 | 600.0 | 3.0 |
| | 万用表 | 6 | 个 | 2000.0 | 1.2 |
| | 锚定主引导条 | 30 | 个 | 1300.0 | 3.9 |
| 荧光腔镜采集系统 | 电子元器件 | 6 | 个 | 2000.0 | 1.2 |
| | TOF 采集模块 | 2 | 个 | 4000.0 | 0.8 |
| | 785nm 激光光源 | 4 | 个 | 5000.0 | 2.0 |
| | 6mm 镜头 FL-CC0614A-2M | 4 | 个 | 3000.0 | 1.2 |
| | 二相色镜 | 5 | 个 | 3000.0 | 1.5 |
| | 纤维内镜 CF-LB2 | 5 | 个 | 2000.0 | 1.0 |
| | 石英光纤 FL-FP03-SH | 5 | 个 | 3000.0 | 1.5 |
| 动物模型 | 比格犬 | 30 | 个 | 4000.0 | 12.0 |
| | 小鼠饲料、垫料 | 730 | 天 | 5.5 | 0.4 |
| | 动物饲养费 | 30 只/ 200 天 | 只·天 | 20.0 | 12.0 |
| | 大动物饲养、运输笼 | 10 | 套 | 4000.0 | 4.0 |
| | 戊巴比妥钠 | 20 | 瓶 | 1500.0 | 3.0 |
| | 异氟烷 | 40 | 瓶 | 500.0 | 2.0 |
| | 动物手术器械 | 8 | 套 | 2000.0 | 1.6 |
| | 一次性注射器 | 40 | 盒 | 100.0 | 0.4 |
| | 用于动物健康护理的兽药等 | 60 | 周 | 200.0 | 1.2 |
| 机械承载装置 | 磁控管 | 1 | 个 | 21000.0 | 2.1 |
| | 软波导 | 2 | 个 | 6000.0 | 1.2 |
| | 焊片 | 20 | 个 | 300.0 | 0.6 |

| 常用范围 | 耗材名称 | 购置数量 | 计量单位 | 单价/元 | 金额/万元 |
|------|-------------------------------------|------|--------|--------|-------|
| 常用范围 | 熔断器 | 20 | 个 | 200.0 | 0.4 |
| | 接线端子 | 30 | 个 | 100.0 | 0.3 |
| | 端板 | 20 | 个 | 150.0 | 0.3 |
| | 连接器 | 10 | 个 | 100.0 | 0.1 |
| | 开关电源 | 5 | 个 | 500.0 | 0.25 |
| | 微动开关 | 10 | 个 | 100.0 | 0.1 |
| | 按钮开关 | 10 | 个 | 100.0 | 0.1 |
| | 光电开关 | 10 | 个 | 800.0 | 0.8 |
| | 集成块 | 4 | 个 | 4000.0 | 1.6 |
| | 集成电路 | 2 | 套 | 4000.0 | 0.8 |
| | 手控器系统 | 2 | 个 | 8000.0 | 1.6 |
| | 无螺丝终端挡块 | 9 | 个 | 300.0 | 0.27 |
| | 保险丝管 | 20 | 个 | 200.0 | 0.4 |
| | 继电器 | 10 | 个 | 800.0 | 0.8 |
| | 微动开关 | 5 | 个 | 500.0 | 0.25 |
| | 配重组件 | 2 | 个 | 5000.0 | 1.0 |
| | 信号采集板 | 3 | 个 | 5000.0 | 1.5 |
| 其他材料 | 惠普 (HP) LaserJet CC388ADtwins 硒鼓 | 10 | 个 | 800.0 | 0.8 |
| | 移动硬盘 | 3 | 个 | 600.0 | 0.18 |
| | 得力 92609 A4 蓝标复印 纸 | 10 | 10 包/箱 | 200.0 | 0.2 |

3. 测试化验加工费 - 5 万元:²

1) 动物实验验证安全性和有效性, 费用合计 1.8 万元³

术中导航结果切片制作与分析: 200 元/蜡块, 需制作和染色分析 90 个蜡块,⁴ 共计 1.8 万元。

2) 对提升项目所需生产设备性能、安全性、可靠性、电磁兼容性进行第三⁵方认证测试, 费用合计 3.2 万元

① 设备性能、安全性、可靠性认证：包括开路电压测试、短路电流测试、温度试验、湿度试验，环境试验等。测试承担单位必须有测试资质（CNAS 认证），项目参与单位均无相关资质。拟委托北京医疗器械检测所进行测试，20000 元/次，需测试 1 次，共计 2 万元；

② 设备电磁兼容性认证：包括静电放电敏感度、脉冲群敏感度、浪涌敏感度、尖峰电压敏感度等。测试承担单位必须有测试资质（CNAS 认证），项目参与单位均无相关资质。拟委托北京医疗器械检测所进行测试，预测试 6000 元/次，需测试 2 次，共计 1.2 万元。

4. 差旅费 -3 万元²

用于项目研究团队骨干参加国内学术会议产生的食宿、交通、会议注册等费用，共计 3 万元。

| 项目 | 金额 |
|----------------|------|
| 交通费（万元） | 0.2 |
| 住宿费（万元/天） | 0.06 |
| 其他补助（万元/人·次） | 0.04 |
| 单人/次费用（万元/人·次） | 0.3 |
| 人·次 | 10.0 |
| 总计（万元） | 3.0 |

5. 会议费 -1 万元⁵

用于参加项目相关学术交流、产品推介等。⁶

6. 信息费（出版/文献/信息传播/知识产权事务费） -10 万元⁷

1) 软件著作权申请费 1.1 万元。

2) 专利、文献等检索查新 6 次，每次费用 5000 元，合计 3 万元。

3) 预计申请国家发明专利 7 件，专利事务费约 5000 元/件，共 3.5 万元。

4) 发表国内核心期刊论文 6 篇，文章版面费、审稿费平均 0.4 万元/篇，需 2.4 万元。

7. 专家咨询费 -2 万元⁹

| 人员分类 | 人数 | 天数 | 次数 | 支出标准（元/人天） | 金额（万元） |
|--------|----|----|----|------------|--------|
| 专业技术人员 | 5 | 2 | 4 | 500.0 | 2.0 |

| | |
|----|-----|
| 合计 | 2.0 |
|----|-----|

8. 劳务费 - 3 万元²

| 人员分类 | 人数 | 投入时间（月） | 支出标准（元/人月） | 金额（万元） |
|--------|----|---------|------------|--------|
| 研究生 | 5 | 8 | 400.0 | 1.6 |
| 临时聘用人员 | 1 | 7 | 2000.0 | 1.4 |
| 合计 | | | | 3.0 |

9. 其他支出 - 1 万元⁴

用于项目相关资料打印、设备邮寄等。⁵

10. 管理费 - 30 万元⁶

项目申请单位的项目管理费等。⁷

11. 绩效支出 - 5 万元⁸

用于对项目组成员的奖励对项目组成员的奖励等。⁹

二、项目实施和申请资金的主要依据¹⁰

1. 国家和我省各类规划¹¹

(1) 《战略性新兴产业重点产品和服务指导目录》[国家发展和改革委员会¹² 2017 年 第 1 号]

4.2.2 先进治疗设备及服务¹³

肿瘤治疗设备。包括具有实时的运动跟踪、图像引导、适形、¹⁴调强等先进功能的电子直线加速器、质子/重离子回旋加速器的放射治疗系统及其高精度治疗计划系统；磁感应、高强度聚焦超声（HIFU）、射频、微波、氩氦刀等肿瘤热疗、消融、冷疗设备及其治疗监测系统；硼中子捕捉治疗系统及其靶向药物。

手术治疗设备。包括术中定位、术中成像、术中监护、影像¹⁵导航等设备及其信息系统；数字化、一体化的外科手术、介入治疗、术中治疗、微创治疗等混合手术室设备及其信息系统；腹腔、胸腔、泌尿、骨科、介入等手术辅助机器人及其配套微创手术器械；高性能的激光、超声、等离子、高频等新型手术器，具有麻醉深度监测和控制等功能的数字麻醉机工作站。

《战略性新兴产业重点产品和服务指导目录》指出，战略性新兴产业中先进治疗设备及服务中所支持的手术治疗设备，包括术中定位、术中成像、影像导航等设备及其信息系统；数字化外科手术、术中治疗手术室设备及其信息系统；腹腔胸腔等手术配套微创手术器械。¹

(2)《陕西省高新技术产业发展条例》[陕西省第十一届人民代表大会常务委员会第十四次会议通过]²

第十三条□鼓励企业、高等院校、科研机构组建或者联合组建工程（技术）研究中心、企业技术中心、工程实验室、重点实验室、企业孵化基地和中间试验基地。符合国家和本省有关规定的，可以申请专项资金和配套资金。←³

省、设区的市发展和改革、科学技术、工业和信息化等有关行政主管部门应当组织有条件的工程（技术）研究中心、企业技术中心、工程实验室、重点实验室和中间试验基地申报国家级、省级认定。←⁴

《陕西省高新技术产业发展条例》指出，鼓励企业、高等院校、科研机构组建或者联合组建工程（技术）研究中心、企业技术中心、工程实验室、重点实验室、企业孵化基地和中间试验基地。⁵

第六条□县级以上人民政府及有关部门应当优化高新技术产业化管理服务，采取政策引导、提高行政效率、落实税收优惠、推动产学研结合、建立科技转化平台、鼓励风险投资、人才培养培训等多种方式，促进企业成为高新技术产业化投资主体，发挥市场机制在高新技术产业发展中的主导作用。←⁶

要鼓励企业、高等院校、科研机构组建或者联合组建工程（技术）研究中心、¹
企业技术中心、工程实验室、重点实验室、企业孵化基地和中间试验基地。

2. 省委省政府工作报告：²

《陕西省 2022 年政府工作报告》³

http://www.shaanxi.gov.cn/zfxxgk/zfgzbg/szfgzbg/202201/t20220124_2208694.html⁴

加快“数字化”促进融合提质。实施新型基础设施提升工程，加大对5G网络、新一代互联网、物联网等重点领域的投资力度，建好国家超算西安中心，着力培育引进数字经济龙头企业、工业互联网平台企业，创建国家数字经济创新发展试验区。发展数字经济核心产业，突破提升以集成电路、新型显示、新型计算等为重点的电子产业，积极培育以区块链、人工智能、卫星互联网、空天地海一体化为重点的新兴数字产业，加快发展数字创意和数据服务产业。推动重点产业数字化转型，实施“上云用数赋智”行动，开展智能生产线、数字化车间、智慧工厂建设，促进传统制造业、服务业、农业等领域数字化赋能、全方位升级。我们一定协同推动数字产业化和产业数字化，全面促进数字技术与实体经济联动发展，打造数字经济新业态，构筑高质量发展新优势。⁵

《陕西省 2022 年政府工作报告》指出，要加快“数字化”促进融合提质，⁶
着力培育引进数字经济龙头企业，发展数字经济核心产业，积极培育人工智能等为重点的新兴数字产业，加快发展数据服务产业。推动**重点产业数字化转型**，打造数字经济新业态。

精准提供基本公共服务。健全常住地提供基本公共服务制度。持续增加经费投入和学位供给，保障适龄儿童就近入学，严格实施“双减”政策，稳妥有序规范民办义务教育，全面落实义务教育教师平均工资不低于当地公务员的要求，推动义务教育优质均衡发展。多渠道解决“入园难”问题，系统推进高中阶段教育改革，促进现代职业教育产教融合、提质培优。落实新时代振兴中西部高等教育的政策措施，“一校一策”支持“双一流”建设，推动校地融合发展。改善提升基本医疗卫生保障服务水平，巩固增强公立医院主体地位，推动优质医疗资源扩容下沉，加快国家医学中心、区域医疗中心和紧密型县域医共体建设，促进中医药传承创新发展。积极应对人口老龄化趋势，优化居家社区和医养结合服务供给，稳妥推进“长护险”试点，社区日间照料机构覆盖率达到90%以上，二级以上综合医院老年医学科占比达到50%。实施好三孩生育政策及配套政策，将3岁以⁷

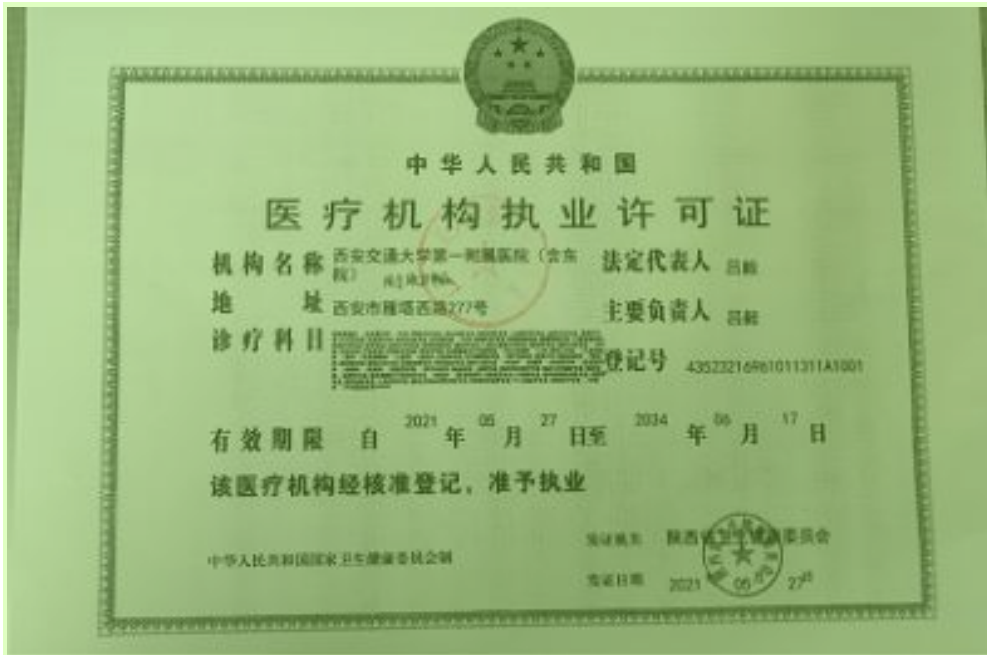精准提供基本公共服务，改善改善提升基本医疗卫生保障服务水平，巩固增⁸
强公立医院主体地位**加快国家医学中心、区域医疗中心和紧密型县域医共体建设。**

3. 文件¹

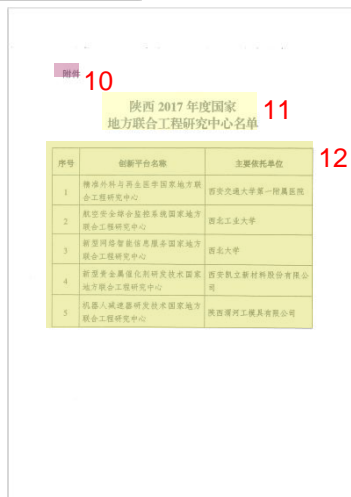

2. 创新平台能力提升项目。创新平台包括已批准的国家工程研究中心、国家企业技术中心以及省级工程研究中心、省级产业创新中心，主要围绕我省信息技术、装备制造、新材料、生物技术、新能源等重点产业发展需求，聚焦新技术、新产品、新工艺等研究开发和成果转化，尤其是对取得高水平标志性成果项目给予重点支持，解决重点领域关键核心技术难题，提升科技成果工程化和系统集成能力，持续不断地为产业创新发展提供成熟的先进技术、工艺以及技术产品和装备，推动产业高端化发展，重点支持有明确的产学研合作机制，在新增产值、利润、产业带动等方面有明确产业贡献的项目。²

《陕西省发展和改革委员会关于组织开展 2023 年度创新平台建设项目征集工作的通知》陕发改高技[2022]2197 号，**创新平台能力提升项目**中围绕我省**信息技术、生物技术**等重点产业发展需要，对取得高水平标志性成果项目给予重点支持，推动产业高端化发展，重点支持有明确产学研合作机制的项目。³

(3) 申请单位：西安交通大学第一附属医院营业执照¹



(4) 平台建设批准文件：精准外科与再生医学国家地方联合工程研究中心³



(5) 平台建设备案文件：陕西省企业投资项目备案确认书¹

陕西省企业投资项目备案确认书²

项目名称：微创化手术智能导航平台建设³

项目代码：2212-610113-04-01-247303⁴

项目单位：西安交通大学医学院第一附属医院⁵

建设地点：陕西省：西安市_雁塔区西安交通大学医学部及第一附属医院⁶

单位性质：事业单位⁷ 建设性质：新建⁸

计划开工时间：2023年02月⁹ 总投资：2500万元¹⁰

建设规模及内容：新建的微创化手术智能导航平台，通过最新的人工智能分析手段，利用多尺度多模态信息融合的大数据分析方法，辅助外科医生对手术患者进行术前方案规划、术中智能导航，提高患者肿瘤精准治疗和生活质量。同时，建成符合现代医学发展及临床需求的青年医生及医学生创新人才培养平台。拟建成集术前规划、术中导航等相关智能设备研发、测试一体化平台，面积约500平方米。¹¹

项目单位承诺：项目符合国家产业政策，填报信息真实、合法和完整。¹²

审核通过¹³

备案机关：西安市雁塔区发展和改革委员会¹⁴

2023年12月29日¹⁵

2. 环评文件¹⁶

西安市环境保护科学研究院
环评报告—2011
环境影响评价报告表¹⁷

评价证书类别：乙 级
评价证书编号：第 3604 号
环评机构和人员¹⁸

西安交通大学医学院第一附属医院科研教学楼¹⁹

环境影响报告书²⁰

西安市环境保护科学研究院²¹

二〇二二年一月²²

建设项目环境影响评价资质证书²³

机构名称：西安市环境保护科学研究院²⁴

住所：西安市雁塔区程家寨中段²⁵

法定代表人：李学军²⁶

证书等级：乙 级²⁷

证书编号：[416]环乙字第 3604 号²⁸

有效期至：至 2031 年 12 月 31 日²⁹

评价范围：³⁰

注：本证书复印件无效。³¹

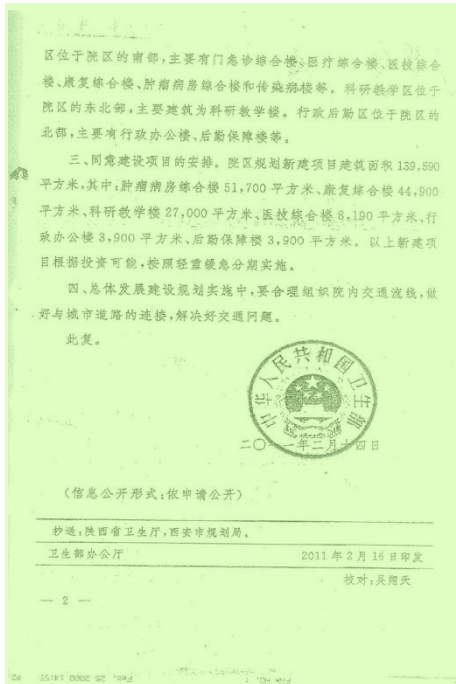
地址：西安市报恩寺街中段（含光门内东侧）³⁴

邮编：710002³⁵


文本类型：环境影响报告书³⁶

项目名称：西安交通大学医学院第一附属医院科研教学楼³⁷

3. 土地证明¹



2



3

4. 规划⁴

按照功能中心建设要求，能力提升⁵

5. 节能⁶

符合相关节能要求⁷

6. 资金来源⁸

总投资：2500.0 万元，其中固定资产：2000.0 万元，自有：500.0⁹ 万元。

7. 前期科技成果证明及真实性证明文件¹

(1) 前期科技成果证明清单:²

1) 获得的科研奖励³

| 序号 | 重要获奖名称 | 级别 | 获奖年度 | 批准单位 |
|----|-------------------------------|-------------------------------------|------|----------------------------|
| 1 | 外科技术重大原始系列创新用磁性器械及装备研发 | 陕西省科学技术奖一等奖 | 2021 | 陕西省人民政府 |
| 2 | 手术语音图文记录系统研发及应用 | 陕西省科学技术奖二等奖 | 2016 | 陕西省人民政府 |
| 3 | 理工医交叉融合的医学创新人才培养路径探索与实践 | 陕西省高等教育教学成果奖一等奖 | 2020 | 陕西省人民政府 |
| 4 | 磁外科技术创新及临床应用 | 陕西省高等学校科学技术奖一等奖 | 2019 | 陕西省教育厅 |
| 5 | 外科急重症时器官功能损伤的机制及防治研究 | 陕西省高等学校科学技术一等奖 | 2021 | 陕西省教育厅 |
| 6 | 用稀土钕铁硼强磁生物效应创新消化外科修复重建技术的系列研究 | 中华医学科技奖一等奖 | 2018 | 中华医学会 |
| 7 | 磁压榨胆肠吻合技术始创、拓展及临床应用 | 教育部技术发明奖一等奖 | 2015 | 教育部 |
| 8 | 智磁科技——磁力助推外科技术大变革 | 第五届中国“互联网+”大学生创新创业大赛金奖 | 2019 | 中国“互联网+”大学生创新创业大赛组织委员会 |
| 9 | 智磁慧用——磁助自动对接血管吻合器 | 第五届“建行杯”中国“互联网+”大学生创新创业大赛陕西赛区省级复赛金奖 | 2019 | 中国“互联网+”大学生创新创业大赛陕西赛区组织委员会 |
| 10 | “梦之手”微小单孔可弯曲腹腔镜手术系统 | 第五届“建行杯”中国“互联网+”大学生创新创业大赛陕西赛区省级复赛银奖 | 2019 | 中国“互联网+”大学生创新创业大赛陕西赛区组织委员会 |

2) 获批的重要基金项目¹

| 序号 | 项目名称 | 项目编号 | 类别 | 执行期限 | 金额 (万元) | 负责人 |
|----|----------------------------------|----------------|-------------------------|-----------------|------------|-----|
| 1 | 国家磁外科学发展战略研究 | 无 | 教育部科技委战略研究 重大项目 | 2022.06-2023.5 | 40 | 吕毅 |
| 2 | 磁外科技术及其基础研究 | 无 | 横向课题 | 2021-2024 | 300 | 吴荣谦 |
| 3 | 外科技术相关磁性器械及装备研发 | 无 | 国家医学中心 | 2022-2023 | 66.67 | 吕毅 |
| 4 | 磁外科基础研究与临床转化创新团队 | 2020TD-040 | 陕西省创新能力 支撑计划 | 2020.01-2023.12 | 50 | 吴荣谦 |
| 5 | 磁锚定技术在内镜下胃肠吻合中的应用研究 | 2020KJXX-022 | 陕西省创新能力 支撑计划 | 2020.05-2022.12 | 10 | 严小鹏 |
| 6 | 磁性胆肠吻合器装置优化设计及静磁场对吻合口生物愈合的调节机制研究 | 82270695 | 国家自然科学基金面上项目 | 2023.01-2026.12 | 72 | 白纪刚 |
| 7 | 多维可控精准磁感应热疗系统的研发 | 2022YFC2408000 | 重点研发计划“诊疗装备与生物医用材料”重点专项 | 2022.11-2025.10 | 200 | 刘晓丽 |
| 8 | 超导匀磁场联合磁吻合技术实现闭锁消化道的重建及评价 | 82170676 | 国家自然科学基金面上项目 | 2022.01-2025.12 | 55 | 刘仕琪 |
| 9 | 利用磁相关技术促进慢性难愈合创面修复及机制 | 82151317 | 国家自然科学基金专项项目 | 2022.01-2024.12 | 100 | 舒茂国 |

²

| 序号 | 项目名称 | 项目编号 | 类别 | 执行期限 | 金额 (万元) | 负责人 |
|----|--|------------------|----------------------|-----------------|------------|-----|
| | 研究 | | | | | |
| 10 | 磁导航气管插管机器人关键技术研究 | 92048202 | 国家自然科学基金 重大研究计划 | 2021.01-2024.12 | 240 | 吕毅 |
| 11 | 基于芯-壳结构复合纳米纤维的磁吻合静脉转流装置的研制及其在离体肝切除中的应用 | 82000624 | 国家自然科学基金 青年项目 | 2021.01-2023.12 | 24 | 刘鹏 |
| 12 | 磁控胶囊 LED 幽门螺杆菌杀灭装置 | 2021GXLH-Z-009 | 陕西省重点研发计划高校联合项目-重点项目 | 2021.05-2023.05 | 50 | 李艳 |
| 13 | 磁胶协同作用血管快速吻合免灌注肝移植技术体系建立 | 2020GXLH-Z-001 | 陕西省高校联合重点项目 | 2020.01-2023.12 | 200 | 吕毅 |
| 14 | 基于光磁导航技术的新冠肺炎患者呼吸道清洁方案研究及产业化 | SQ2020YFF0416030 | 国家重点研发计划项目 | 2020.09-2022.08 | 50 | 董鼎辉 |
| 15 | 电磁声光耦合式无创消化道早癌陡脉冲电场消融系统研制 | 2018YFC0115300 | 科技部重点研发计划项目 | 2018.08-2021.06 | 473 | 吕毅 |

3) 授权的代表性专利¹

平台授权发明专利 80 余项，在申请 20 余项，部分成果已转化，语音图文相关专利已于一七年完成转化，高度²仿真腹腔镜手术模拟训练器械相关专利已于二〇年完成转化，磁控手术系统相关专利已于二〇年完成转化。

| 序号 | 知识产权具体名称 | 授权号 | 授权日期 | 权利人 |
|----|-------------------------|---------------------|------------|-----------------|
| 1 | 外科手术语音图文记录工作系统 V1.0 | 2016 SR 062557 | 2015-10-20 | 西安交通大学第一附属医院 |
| 2 | 一种智能外科手术过程视频记录系统 | ZL 2014 1 0093439.3 | 2016-02-24 | 西安交通大学 |
| 3 | 一种高度仿真腹腔镜手术模拟训练器 | ZL 2014 1 0092602.4 | 2017-06-20 | 西安交通大学 |
| 4 | 一种高度仿真介入手术训练器 | ZL 2014 1 0092846.2 | 2017-04-19 | 西安交通大学 |
| 5 | 一种用于腹腔镜手术的磁性机械臂 | ZL 2011 1 0089915.0 | 2012-11-07 | 西安交通大学 |
| 6 | 一种腹腔镜手术的磁性辅助照明摄像装置 | ZL 2011 1 0090081.5 | 2013-04-17 | 西安交通大学 |
| 7 | 一种集束多臂的智能外科辅助平台 | ZL 2015 1 0106386.9 | 2017-01-25 | 西安交通大学医学院第一附属医院 |
| 8 | 一种双钳道单孔可弯曲腹腔镜系统 | ZL 2018 2 0968149.2 | 2019-06-11 | 西安交通大学医学院第一附属医院 |
| 9 | 一种用于腹腔镜在操作的激光引导器械 | ZL 2018 2 0366014.9 | 2019-04-02 | 西安交通大学医学院第一附属医院 |
| 10 | 一种基于近红外光视觉诊断的磁锚定腹腔镜系统 | ZL 2015 1 0867059.5 | 2017-03-29 | 西安交通大学医学院第一附属医院 |
| 11 | 一种可减少激光作用组织时产生烟雾的手持式装置 | ZL 2018 2 0295048.3 | 2019-04-23 | 西安交通大学医学院第一附属医院 |
| 12 | 一种用于减戳卡腹腔镜手术的磁悬浮视频及照明系统 | ZL 2020 2 0485999.4 | 2021-02-02 | 西安交通大学医学院第一附属医院 |
| 13 | 一种用于内镜下消化道吻合的磁性锚定穿刺组件 | ZL 2018 1 1172739.5 | 2020-11-10 | 西安交通大学医学院第一附属医院 |

| 序号 | 知识产权具体名称 | 授权号 | 授权日期 | 权利人 |
|----|----------------------|---------------------|------------|-----------------|
| 14 | 一种用于单孔腹腔镜的磁性辅助牵拉装置 | ZL 2011 1 0090121.6 | 2012-07-04 | 西安交通大学 |
| 15 | 一种肝胆管空肠吻合和肠肠端侧吻合磁性装置 | ZL 2010 1 0216607.5 | 2012-04-25 | 西安交通大学 |
| 16 | 一种电磁可控性腹腔大血管阻断系统 | ZL 2013 1 0051814.3 | 2015-04-15 | 西安交通大学 |
| 17 | 一种用于磁锚定手术器械的体外锚定系 | ZL 2015 1 0151507.1 | 2016-09-28 | 西安交通大学医学院第一附属医院 |
| 18 | 一种适用于磁外科的吻合器 | ZL 2015 1 0028534.X | 2017-02-22 | 西安交通大学医学院第一附属医院 |
| 19 | 一种铆钉式血管吻合装置 | ZL 2019 2 2205269.4 | 2020-08-25 | 西安交通大学医学院第一附属医院 |
| 20 | 一种磁悬浮颈椎牵引装置 | ZL 2019 2 2000910.0 | 2020-08-25 | 西安交通大学医学院第一附属医院 |

1

4) 发表的代表性文章¹

| 序号 | 作者 | 文章题目 | 期刊 | 年卷期页码 |
|----|---|---|---|-------------------------------|
| 1 | 吕毅, 徐向华, 仵正, 李建辉, 樊林, 王博 | 倡用图文外科手术记录专家共识 | 中华肝脏外科手术学电子杂志 | 2015,4(5):265-267 |
| 2 | 薛召, 胡良硕, 汤博, 张晓刚, 吕毅 | 胆道镜图文手术记录系统的研制及临床试用 | 中国医疗器械杂志 | 1671-7104(2017)06-04 50-03 |
| 3 | 汤博, 崔晓海, 关正, 张晓刚, 吴荣谦, 吕毅 | 外科手术语音图文记录报告系统的研发及临床应用研究 | 中国医学教育技术 | 2016,4(30):194-197 |
| 4 | 吕毅, 汤博, 薛召, 史爱华, 吴荣谦 | 外科手术语音图文工作站——探索数字化精准教学新模式 | 临床医学研究与实践 | 2096-1413(2016)11-00 06-03 |
| 5 | Liu Kang, Yang Hang, Huang Gaobo, Shi Aihua, Lu Qiang, Qiao Wei, Wang Haohua, Ke Mengyun, Ding Hongfan, Wang Rongfeng, Wang Kailing, Feng Hui, Suo Zhigng, Tang Jingda, Lv Yi | Adhesive anastomosis for organ transplantation | Bioactive Materials | 2022,13(3):260-268 |
| 6 | Dong Jian, Ke Mengyun, Wu Xiaoning, Ding Hongfan, Zhang, Lina, Ma Feng, Liu Xuemin, Wang Bo, Liu Jianlin, Lu Shaoying, Wu Rongqian, Pawlik Timothy M, Lyu Yi, Zhang Xufeng | SRY is a key mediator of sexual dimorphism in hepatic ischemia/reperfusion injury | Annals of Surgery | 2022,276(2):345-356 |
| 7 | Bai Jigang, Yue Wang, Yong Zhang, Yi Lv and Int Sci Comm Third | Expert Consensus on the Application of the Magnetic Anchoring and Traction | Hepatobiliary & Pancreatic Diseases International | 2022,21(1):7-9 |

2

| 序号 | 作者 | 文章题目 | 期刊 | 年卷期页码 |
|----|---|---|--|-----------------------|
| | | Technique in Thoracoscopic and Laparoscopic Surgery | | |
| 8 | Bin Yan, Chen Liu, Siyao Wang, Hugang Li, Ju Jiao, Wee Siang Vincent Lee, Song Zhang, Yayi Hou, Yuzhu Hou, Xiaowei Ma, Haiming Fan, Yi Lv, Xiaoli Liu | Magnetic hyperthermia induces effective and genuine immunogenic tumor cell death with respect to exogenous heating | Journal of Materials Chemistry B | 2022,10(28):5364-5374 |
| 9 | Junke Fu, Yunhao Li, Ziwei Wang, Yuan Cheng, Nanzheng Chen, Xin Sun, Boxiang Zhang, Ziyang Peng, Wenwen Chen, Rongkai Qian, Aihua Shi, Xiaopeng Yan, Haohua Wang, Feng Ma, Yi Lv, Yong Zhang | The role of magnetic anchoring and traction technique in thoracoscopic lymphadenectomy along the left recurrent laryngeal nerve | Surgical Endoscopy and other Interventional Techniques | 2022,36(5):3653-3662 |
| 10 | Zhe Feng, Shan-Pei Wang, Hao-Hua Wang, Qiang Lu, Wei Qiao, Kai-Ling Wang, Hong-Fan Ding, Yue Wang, Rong-Feng Wang, Ai-Hua Shi, Bing-Yi Ren, Yu-Nan Jiang, Bin He, Jia-Wei Yu, Rong-Qian Wu, Yi Lv | Magnetic-assisted laparoscopic liver transplantation in swine | Hepatobiliary & pancreatic diseases international : HBPD INT | 2022,21(4):340-346 |
| 11 | Yu Li, Nan Zhang, Yi Lv | Expert consensus on magnetic recanalization technique for biliary anastomotic strictures after liver transplantation | Hepatobiliary Surgery and Nutrition | 2021, 10(3):401-404 |
| 12 | Zhang Xiaogang, Liu Xuemin, Wang Shanpei, Lu Qiang, Shi Aihua, Li Yu, Qian Yerong, Liu Kang, Ma Feng, Wang | Fast Vascular Reconstruction With Magnetic Devices in Liver Transplant: A | Liver Transplantation | 2021, 27(2):286-290 |

| 序号 | 作者 | 文章题目 | 期刊 | 年卷期页码 |
|----|---|--|--------------------------------|-------------------------|
| | Haohua, Li Yongli, Wu Rongqian, Zhang Xufeng, Wang Bo, Lv Yi | Novel Surgical Technique | | |
| 13 | Shengzhen Liu, Yichao Chai, Enqiang Linghu, Bo Zhang, Ningli Chai, Yi Lv, | Magnetic multidirectional anchor-guided endoscopic submucosal tunnel dissection for large gastric lesions | Endoscopy | 2021,53(10):E382- E383 |
| 14 | Hong Lei, Yi Pan, Rongqian Wu, Lv Yi | Innate Immune Regulation Under Magnetic Fields With Possible Mechanisms and Therapeutic Applications | Frontiers in Immunology | 2020,11:582772 |
| 15 | Wang Yue, Chen Huan, Tang Bo, Ma Tao, Li Qingshan, Zhu Haoyang, Zhang Xiaogang, Lv Yi, Dong Dinghui | Magnetic spiderman, a new surgical training device: study of safety and educational value in a liver transplantation surgical training program | World Journal of Surgery | 2020, 44(4): 1062- 1069 |
| 16 | Ma Tao, Chai Yichao, Zhu Haoyang, Chen Huan, Wang Yue, Li Qingshan, Pang Lihui, WuRongqian, Lv Yi, Dong Dinghui | Effects of different 980-nm diode laser parameters in hepatectomy | Lasers in Surgery and Medicine | 2019, 51(8): 720-726 |
| 17 | Zhu Haoyang, Shang Yafei, Ma Tao, Wang Yue, Wu Rongqian, Lv Yi, Dong Dinghui | 10-mm laparo-endoscopic single-site cholecystectomy using multiple magnetically anchored and controlled | Journal of Surgical Research | 2019, 239: 166-172 |

| 序号 | 作者 | 文章题目 | 期刊 | 年卷期页码 |
|----|---|--|---|----------------------------|
| | | instruments | | |
| 18 | Xiaohai Cui , Peng Lei , Shiqi Liu, Xuemin Liu , Zheng Wu , Yi Lv | A sutureless method for digestive tract reconstruction during pancreaticoduodenectomy in a dog model | International Journal of Clinical and Experimental Medicine | 2015 Jan 15;8(1):289-96 |
| 19 | Yan Li , Na Li , Qunying Han , Shuixiang He , Ricard S Bae , Zhengwen Liu , Yi Lv , Bingyin Shi | Performance of physical examination skills in medical students during diagnostic medicine course in a University Hospital of Northwest China | PLoS One | 2014 Oct 15;9(10): e109294 |
| 20 | X Liu. H Feng Y Fu. Y Lv | Mechanical design of wireless in vivo robot unit for surgical vision | IEEE TransBiomed Eng | 2009 Jun;56(6):1700 - 1710 |

5) 获批建设的平台或重点实验室¹

| 序号 | 平台名称 | 获批时间 | 批准单位 |
|----|-----------------------|---------|-------------|
| 1 | 陕西省再生医学中心与外科工程研究中心 | 2012.09 | 陕西省发展和改革委员会 |
| 2 | 精准外科与再生医学国家地方联合工程研究中心 | 2018.01 | 国家发展和改革委员会 |

(2) 科技成果真实性证明文件:³

1) 获得的科研奖励:⁴

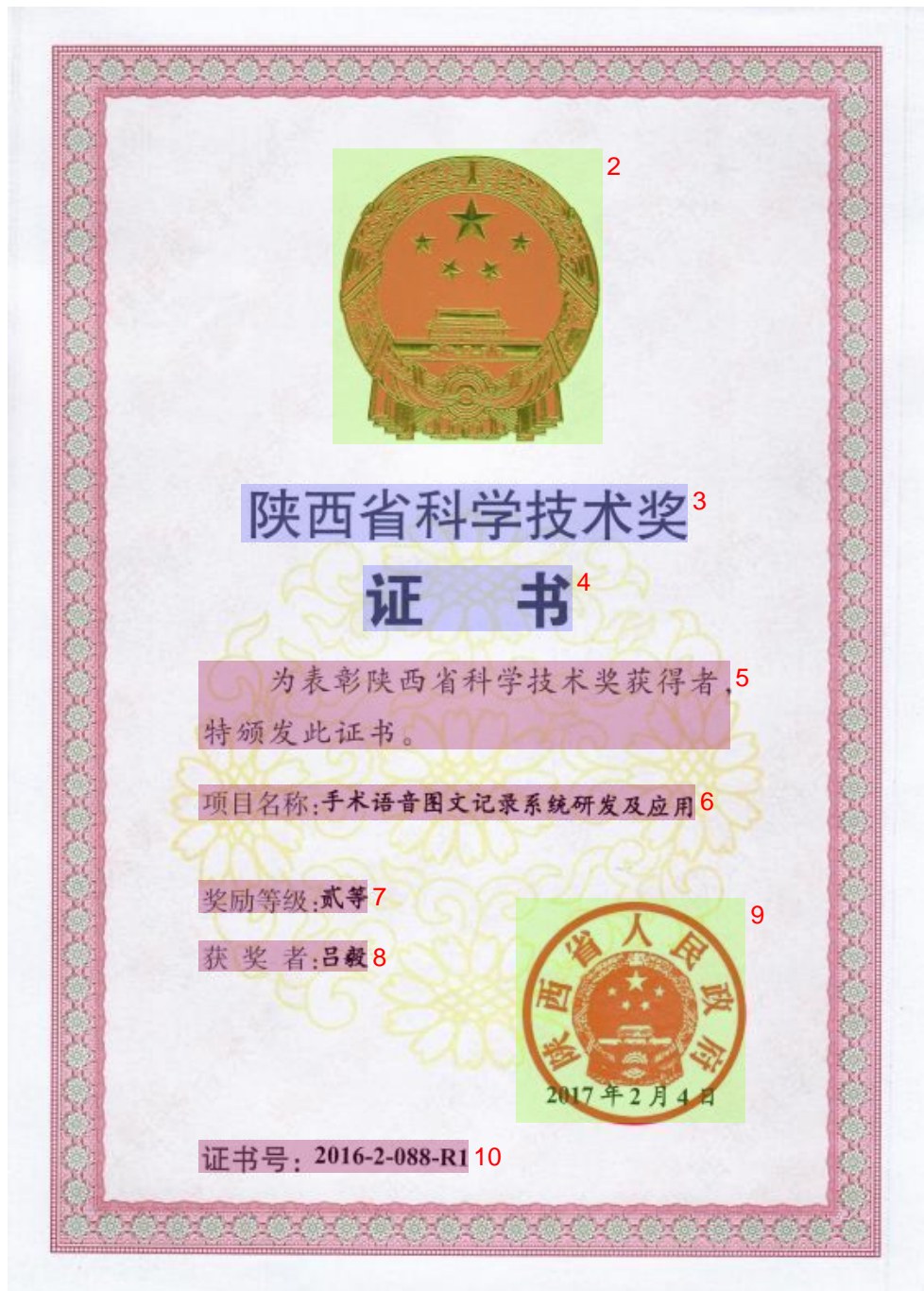1. 外科技术重大原始系列创新用磁性器械及装备研发⁵

省政府公报 2022·10⁶

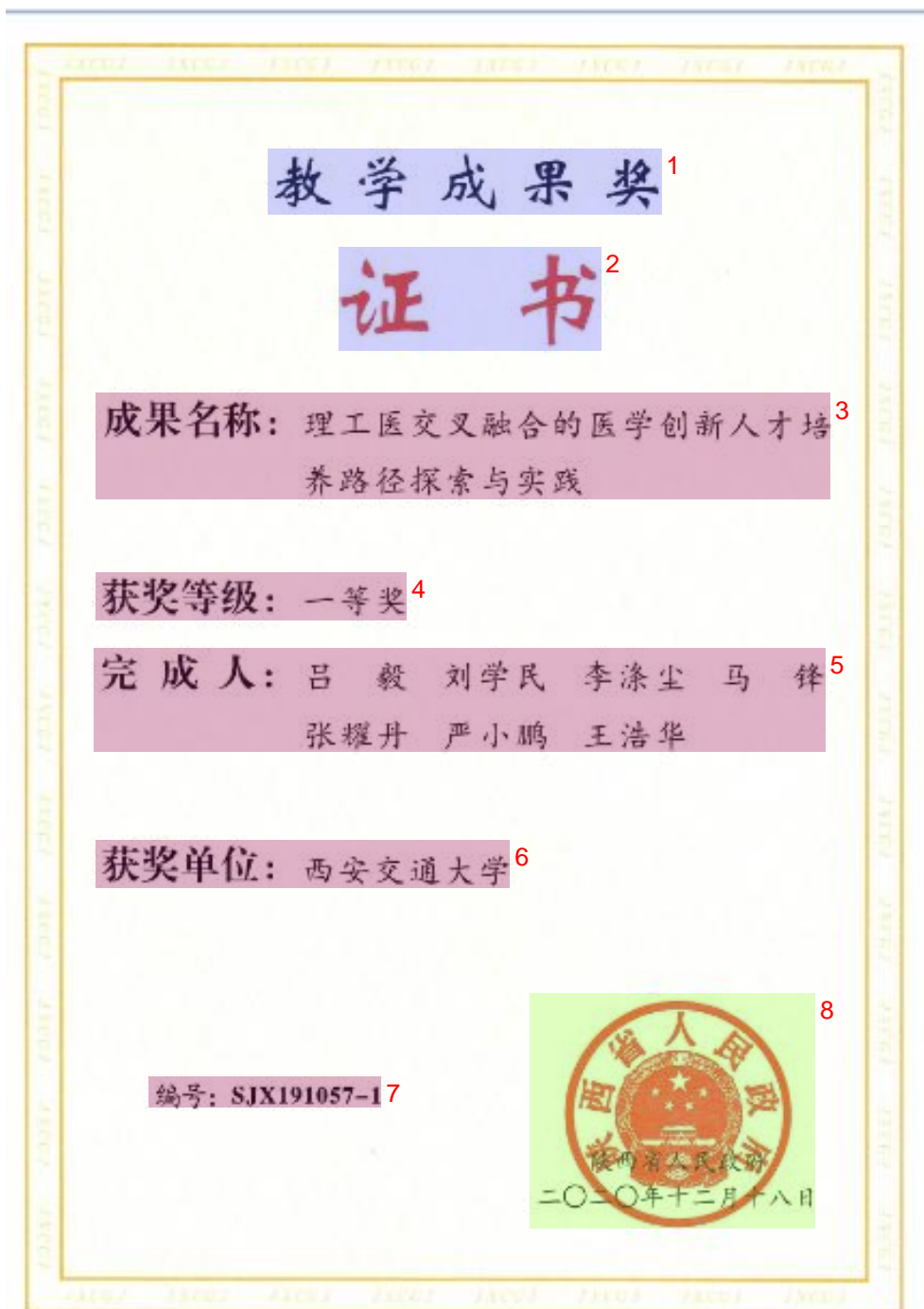省政府文件⁷

| 序号 | 编号 | 项目名称 | 主要完成人 | 主要完成单位 | 提名单位 (专家) |
|----|----------|------------------------|---|--------|-----------|
| 15 | 20214508 | 外科技术重大原始系列创新用磁性器械及装备研发 | 吕毅, 刘学民, 严小鹏, 张谓丰, 马锋, 汤博, 李宇, 白纪刚, 王善佩, 李奇灵, 任牡丹 | 西安交通大学 | 陕西省医学会 |

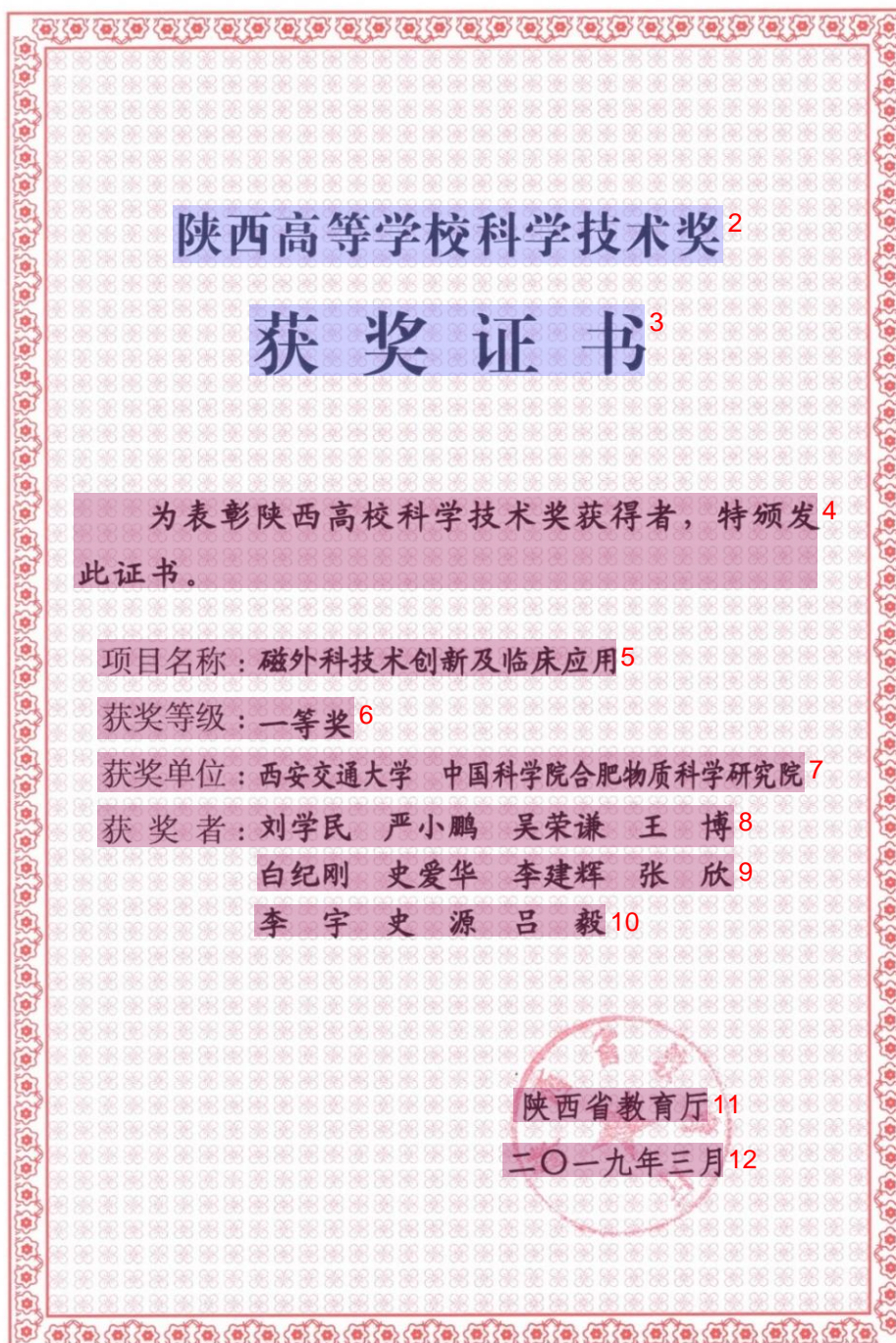2. 手术语音图文记录系统研发及应用¹



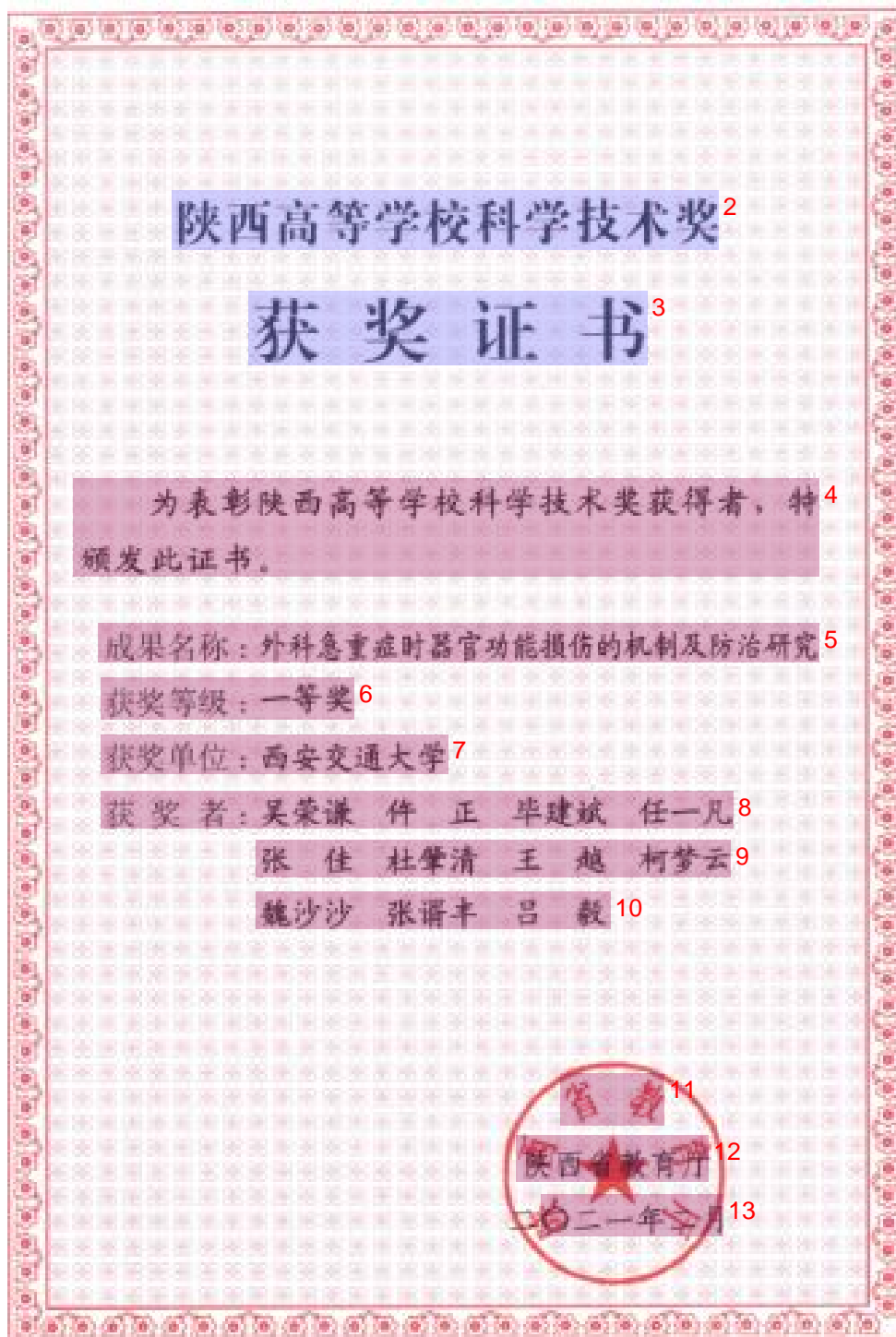3. 理工医交叉融合的医学创新人才培养路径探索与实践



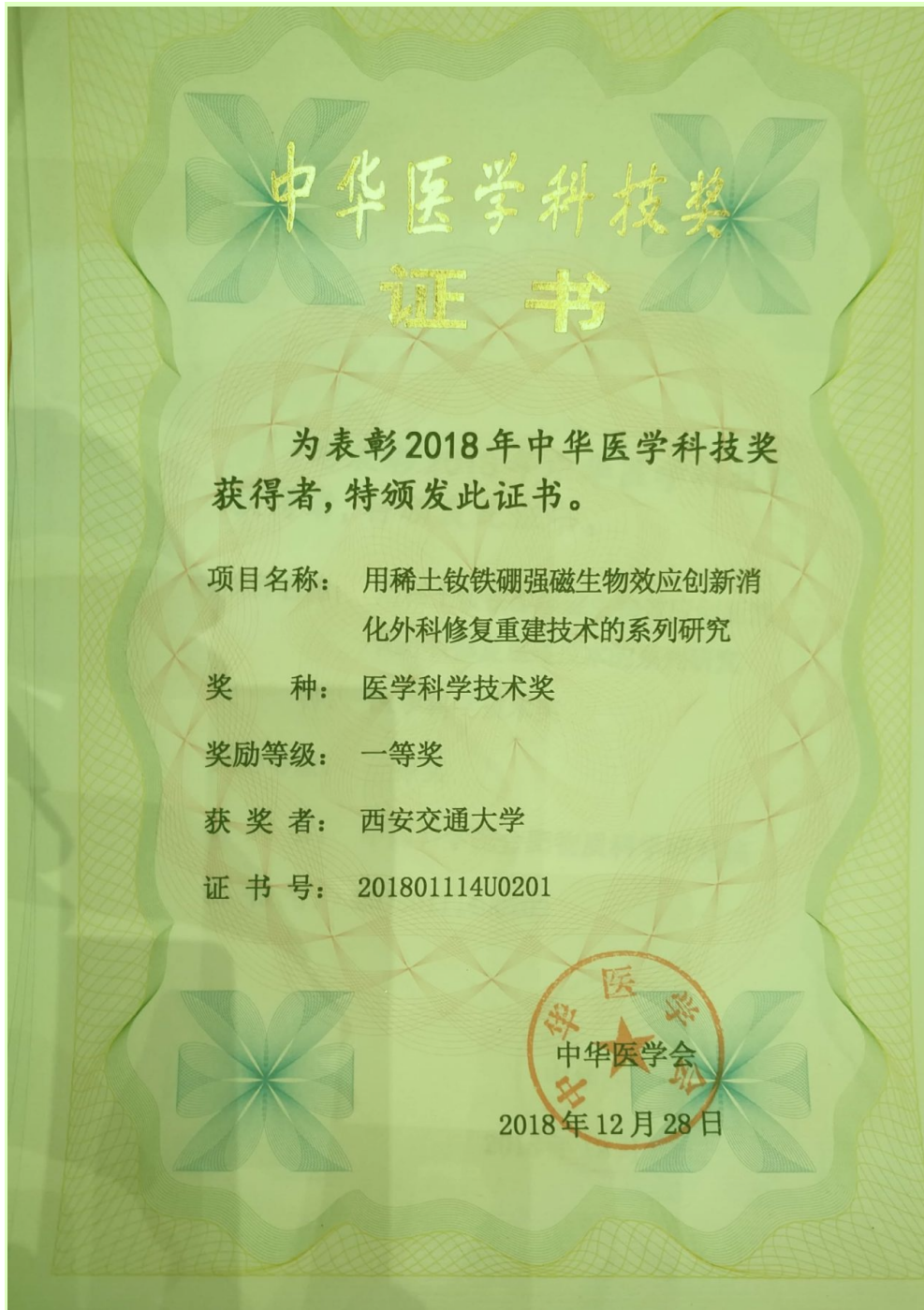4. 磁外科技术创新及临床应用¹



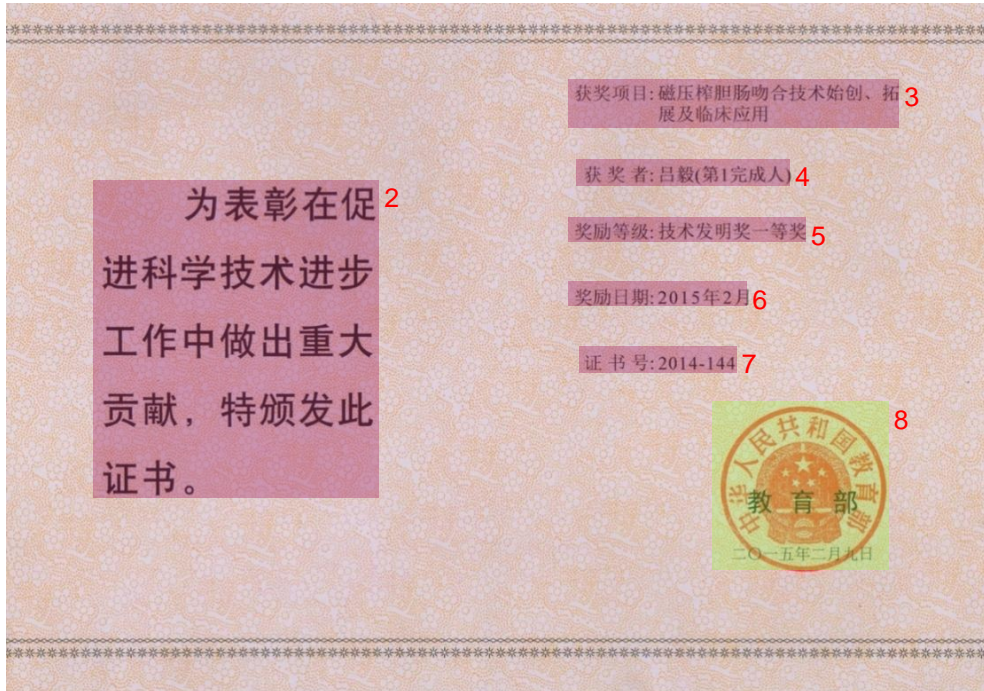
5. 外科急重症时器官功能损伤的机制及防治研究¹



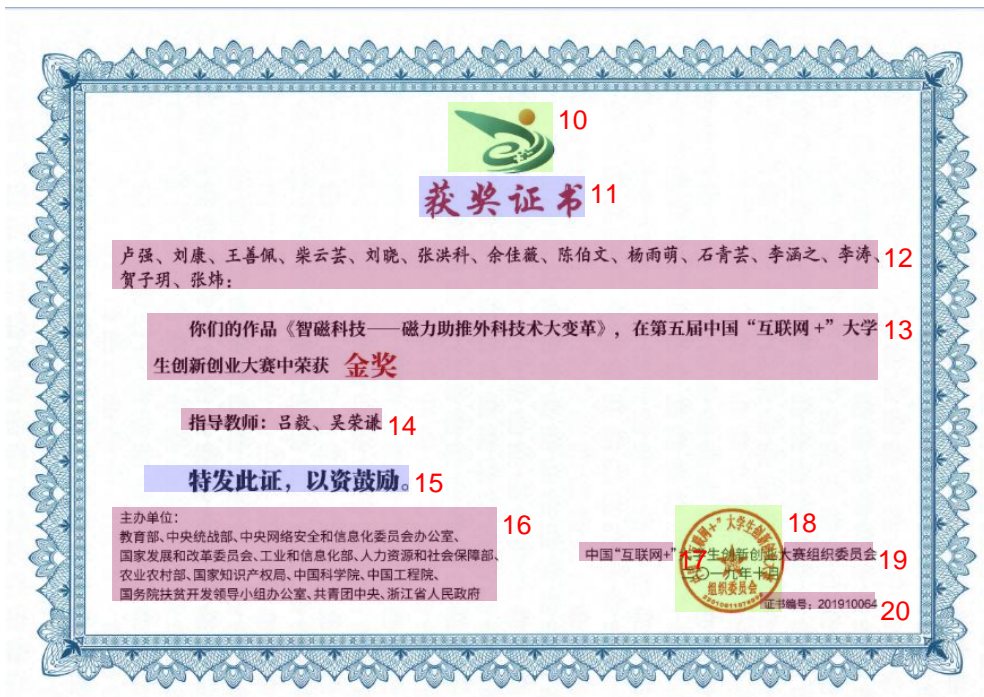6. 用稀土钆铁硼强磁生物效应创新消化外科修复重建技术的系列研究¹



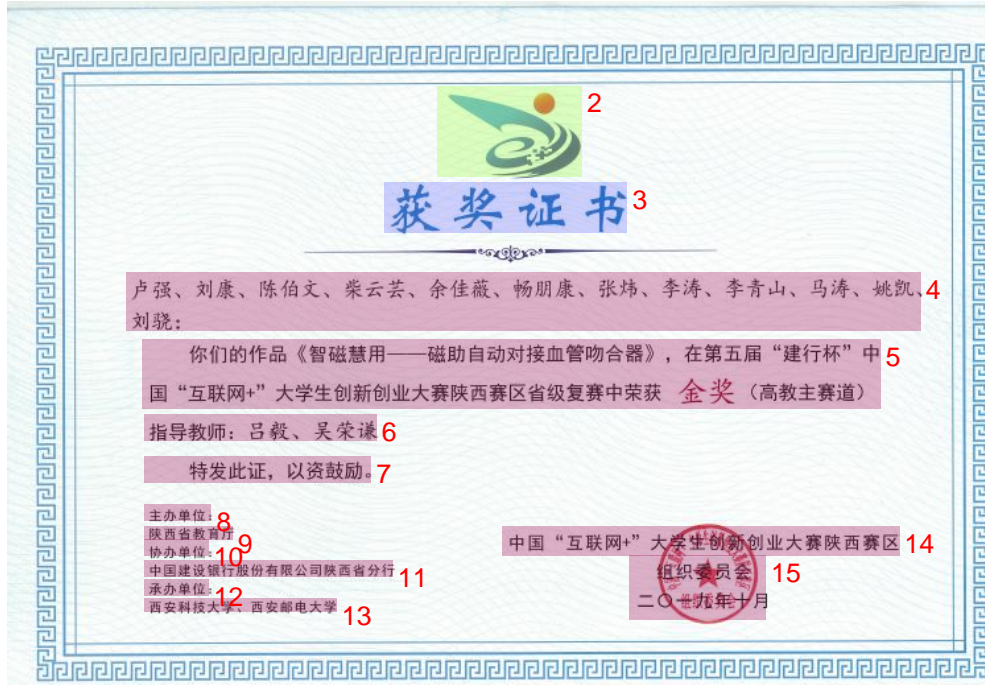7. 磁压榨胆肠吻合技术始创、拓展及临床应用¹



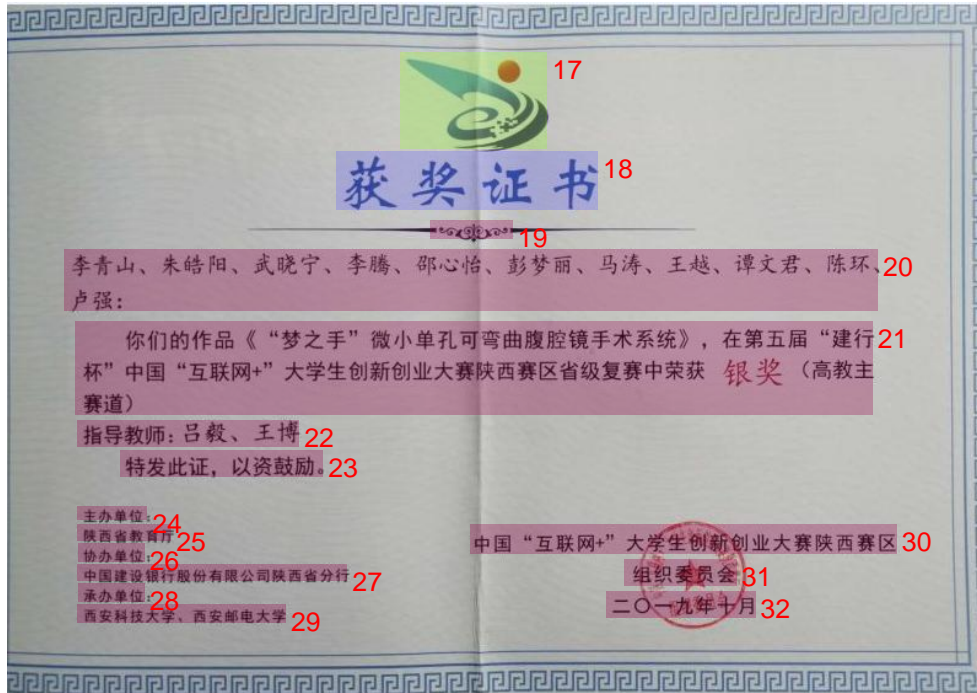
8. 智磁科技——磁力助推外科技术大变革⁹



9. 智磁慧用—磁助自动对接血管吻合器¹

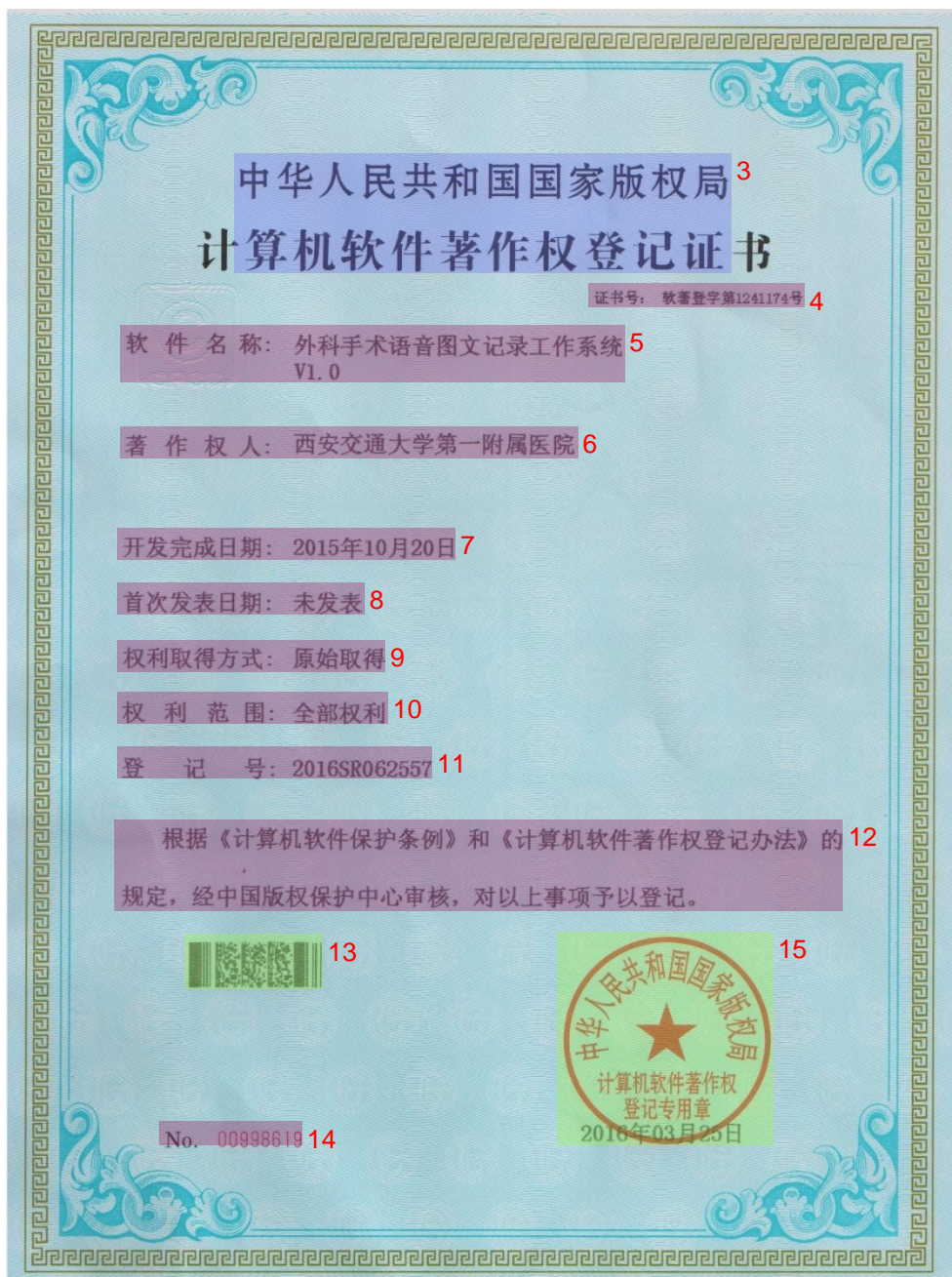


10. “梦之手”微小单孔可弯曲腹腔镜手术系统¹⁶




2) 授权的代表性专利证明:1


1. 外科手术语音图文记录工作系统 V1.0 2



2. 一种智能外科手术过程视频记录系统¹

证书号第 1964387 号²

³

⁴

发明专利证书⁵

发明名称：一种智能外科手术过程视频记录系统⁶

发明人：吕毅；董鼎辉；潘西川；马锋；刘学民⁷

专利号：ZL 2014 1 0093439.3⁸

专利申请日：2014 年 03 月 13 日⁹


专利权人：西安交通大学¹⁰

授权公告日：2016 年 02 月 24 日¹¹


本发明经过本局依照中华人民共和国专利法进行审查，决定授予专利权，颁发本证书¹²并在专利登记簿上予以登记。专利权自授权公告之日起生效。


本专利的专利权期限为二十年，自申请日起算。专利权人应当依照专利法及其实施细则¹³则规定缴纳年费。本专利的年费应当在每年 03 月 13 日前缴纳。未按照规定缴纳年费的，专利权自应当缴纳年费期满之日起终止。

专利书记载专利权登记时的法律状况。专利权的转移、质押、无效、终止、恢复和¹⁴专利权人的姓名或名称、国籍、地址变更等事项记载在专利登记簿上。

¹⁵

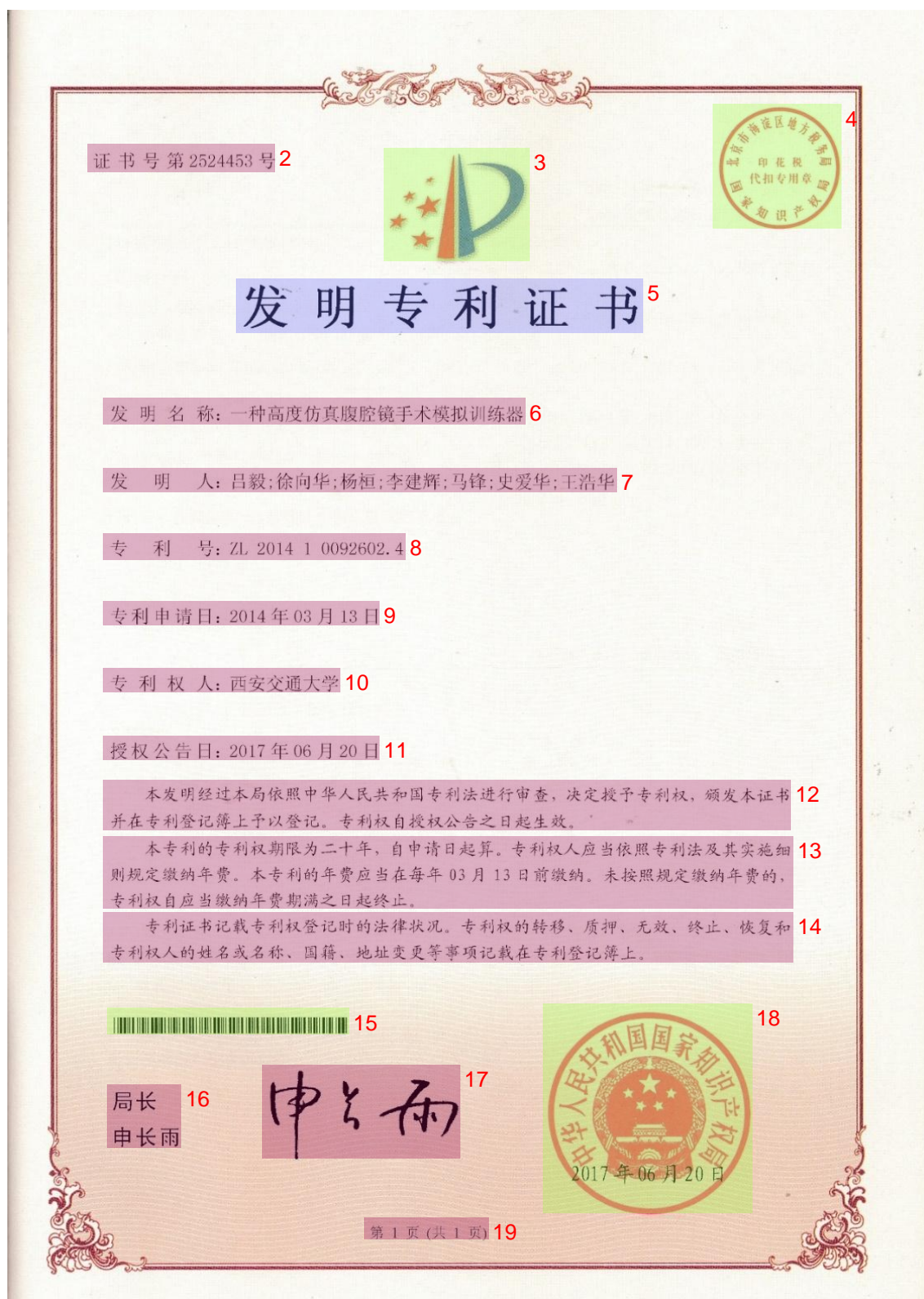
局长¹⁶
申长雨

¹⁷

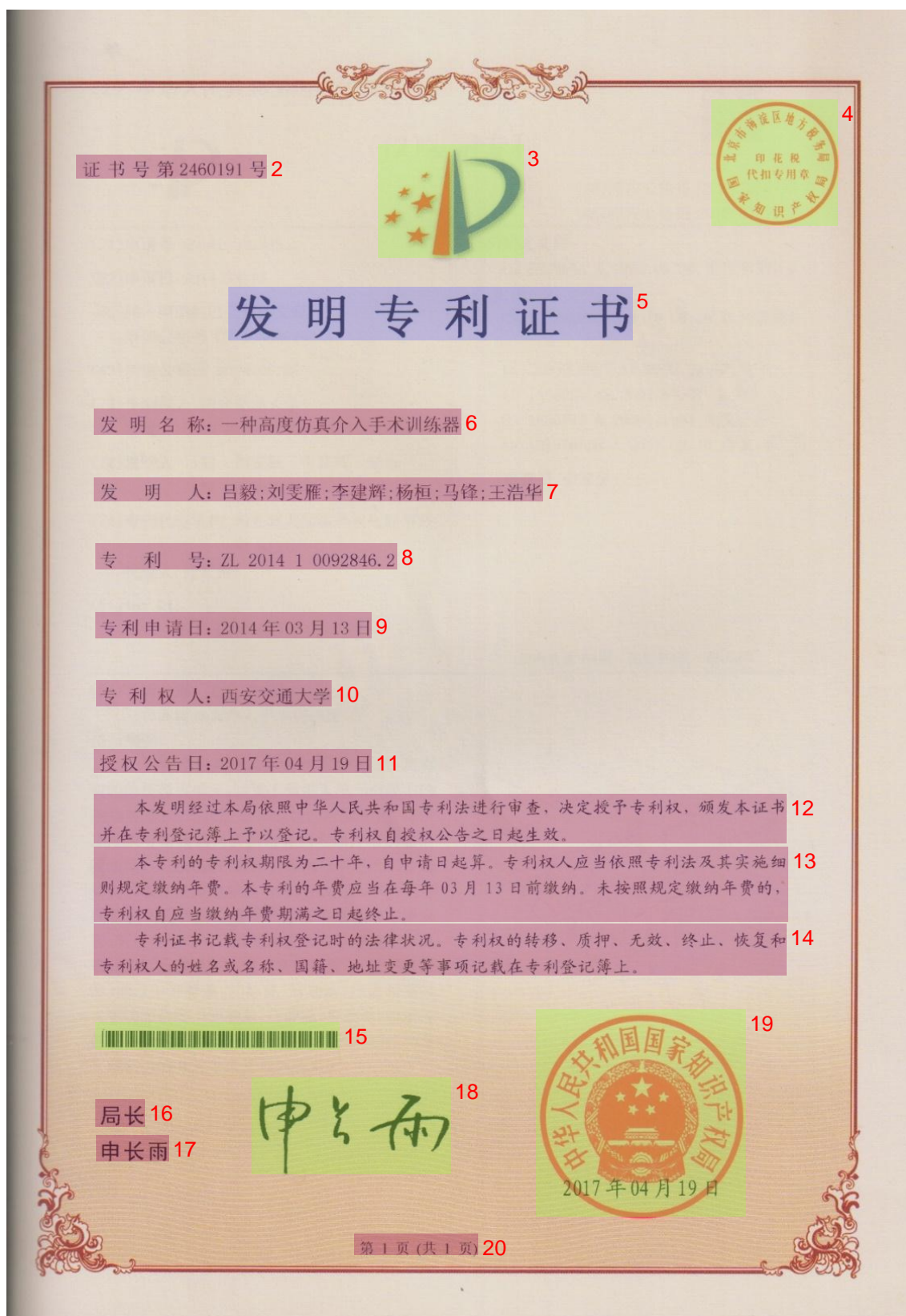
¹⁸
2016 年 02 月 24 日

第 1 页 (共 1 页)¹⁹

3. 一种高度仿真腹腔镜手术模拟训练器¹





4. 一种高度仿真介入手术训练器¹



5. 一种用于腹腔镜手术的磁性机械臂¹

证书号第1073805号²

³

⁴

发明专利证书⁵

发明名称：一种用于腹腔镜手术牵拉的磁性机械臂⁶

发明人：吕毅;黄石;付宜利;缪骥;董鼎辉⁷

专利号：ZL 2011 1 0089915.0⁸

专利申请日：2011年04月11日⁹


专利权人：西安交通大学¹⁰


授权公告日：2012年11月07日¹¹


本发明经过本局依照中华人民共和国专利法进行审查，决定授予专利权，颁发本证书并在专利登记簿上予以登记。专利权自授权公告之日起生效。¹²

本专利的专利权期限为二十年，自申请日起算。专利权人应当依照专利法及其实施细则规定缴纳年费。本专利的年费应当在每年04月11日前缴纳。未按照规定缴纳年费的，专利权自应当缴纳年费期满之日起终止。¹³

专利证书记载专利权登记时的法律状况。专利权的转移、质押、无效、终止、恢复和专利权人的姓名或名称、国籍、地址变更等事项记载在专利登记簿上。¹⁴

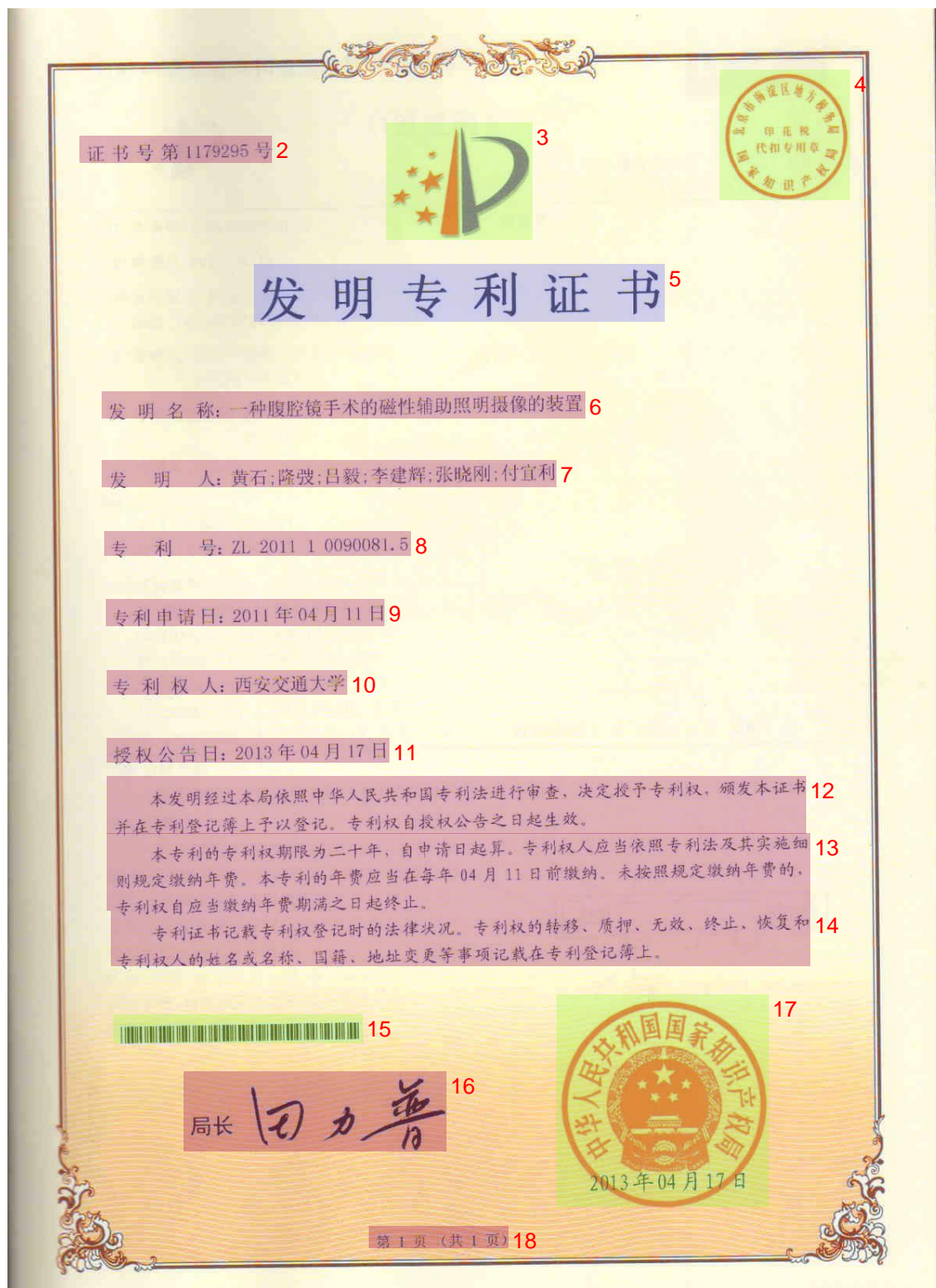
¹⁵

局长¹⁶ ¹⁷

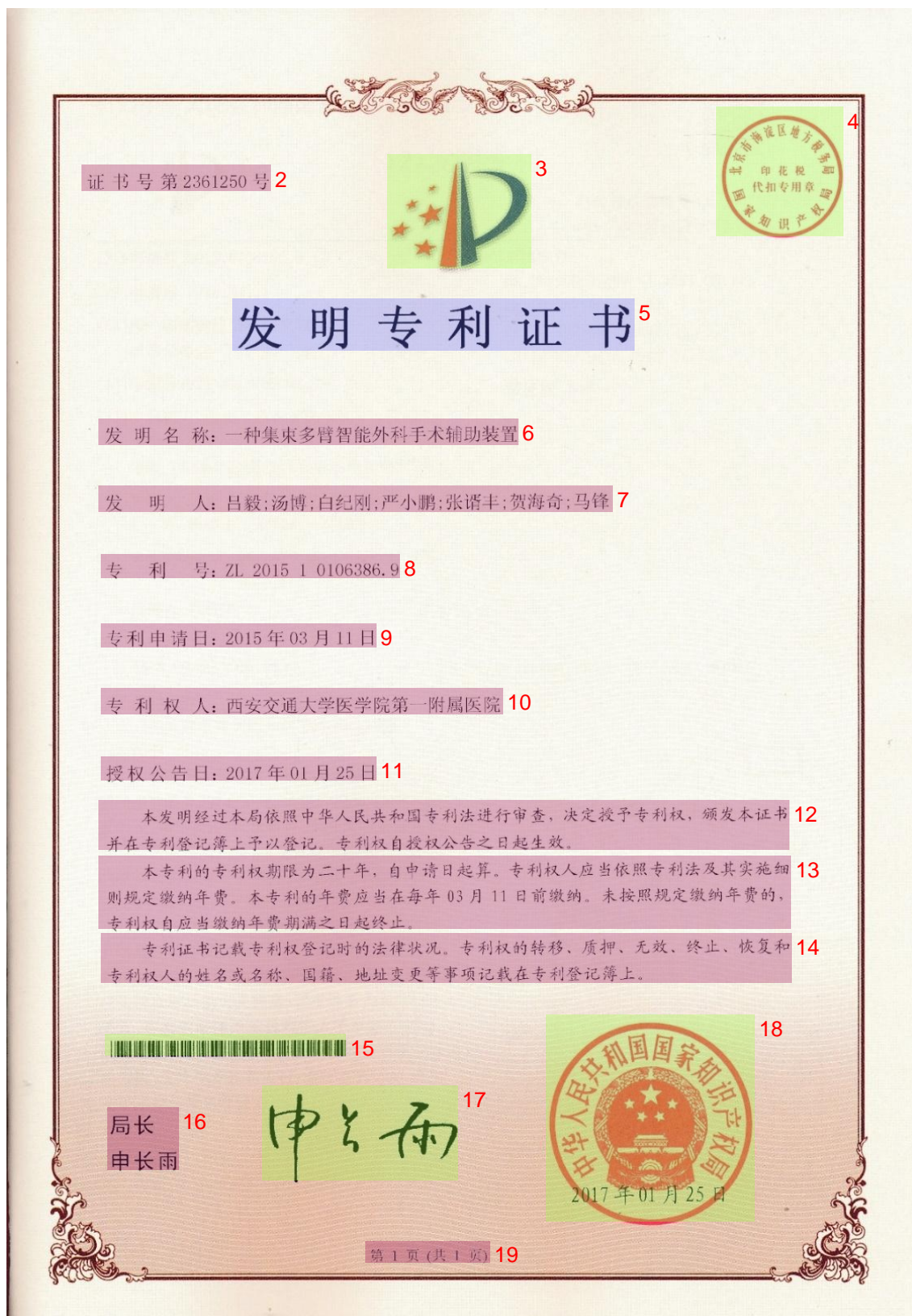
¹⁸
2012年11月07日

第1页 (共1页)¹⁹

6. 一种腹腔镜手术的磁性辅助照明摄像装置¹



7. 一种集束多臂的智能外科辅助平台¹



8. 一种双钳道单孔可弯曲腹腔镜系统¹

证书号第8951170号²



实用新型专利证书⁵

实用新型名称：一种双钳道单孔可弯曲腹腔镜系统⁶

发明人：吕毅；潘西川；马锋；仵正；吴荣谦；朱皓阳；李宇；刘学民⁷
王博

专利号：ZL 2018 2 0968149.2⁸

专利申请日：2018年06月22日⁹

专利权人：西安交通大学医学院第一附属医院¹⁰
西安西川医疗器械有限公司

地址：710061 陕西省西安市雁塔西路277号¹¹

授权公告日：2019年06月11日¹² 授权公告号：CN 208958192 U¹³

国家知识产权局依照中华人民共和国专利法经过初步审查，决定授予专利权，颁发实用新型专利证书并在专利登记簿上予以登记。专利权自授权公告之日起生效。专利权期限为十年，自申请日起算。¹⁴

专利证书记载专利权登记时的法律状况。专利权的转移、质押、无效、终止、恢复和专利权人的姓名或名称、国籍、地址变更等事项记载在专利登记簿上。¹⁵



局长¹⁷
申长雨


申长雨¹⁸





第1页(共2页)²⁰

其他事项参阅背面²¹

9. 一种用于腹腔镜在操作的激光引导器械



证书号第 8669327 号 ¹  ²  ³

实用新型专利证书 ⁴

实用新型名称：一种用于腹腔镜下操作的激光引导器械 ⁵

发 明 人：吕毅；柴伟超；庞利辉；吴荣谦；马涛；杨桓；胡良硕；马锋 ⁶
乔玮；单丽宇；姜楠

专 利 号：ZL 2018 2 0366014.9 ⁷

专利申请日：2018 年 03 月 19 日 ⁸




专 利 权 人：西安交通大学医学院第一附属医院 ⁹

地 址：710061 陕西省西安市雁塔西路 277 号 ¹⁰

授权公告日：2019 年 04 月 02 日 ¹¹ 授权公告号：CN 208677572 U ¹²

国家知识产权局依照中华人民共和国专利法经过初步审查，决定授予专利权，颁发实用 ¹³
新型专利证书并在专利登记簿上予以登记。专利权自授权公告之日起生效。专利权期限为十
年，自申请日起算。

专利证书记载专利权登记时的法律状况。专利权的转移、质押、无效、终止、恢复和专 ¹⁴
利权人的姓名或名称、国籍、地址变更等事项记载在专利登记簿上。

 ¹⁵  ¹⁷  ¹⁸
局长 ¹⁶
申长雨
2019 年 04 月 02 日

第 1 页 (共 2 页) ¹⁹

其他事项参见背面 ²⁰

10. 一种基于近红外光视觉诊断的磁锚定腹腔镜系统¹

证书号第8951170号²



实用新型专利证书⁵

实用新型名称：一种双钳道单孔可弯曲腹腔镜系统⁶

发明人：吕毅；潘西川；马锋；仵正；吴荣谦；朱皓阳；李宇；刘学民⁷
王博

专利号：ZL 2018 2 0968149.2⁸

专利申请日：2018年06月22日⁹

专利权人：西安交通大学医学院第一附属医院¹⁰
西安西川医疗器械有限公司

地址：710061 陕西省西安市雁塔西路277号¹¹

授权公告日：2019年06月11日¹² 授权公告号：CN 208958192 U¹³

国家知识产权局依照中华人民共和国专利法经过初步审查，决定授予专利权，颁发实用新型专利证书并在专利登记簿上予以登记。专利权自授权公告之日起生效。专利权期限为十年，自申请日起算。¹⁴

专利证书记载专利权登记时的法律状况。专利权的转移、质押、无效、终止、恢复和专利权人的姓名或名称、国籍、地址变更等事项记载在专利登记簿上。¹⁵



局长¹⁷
申长雨

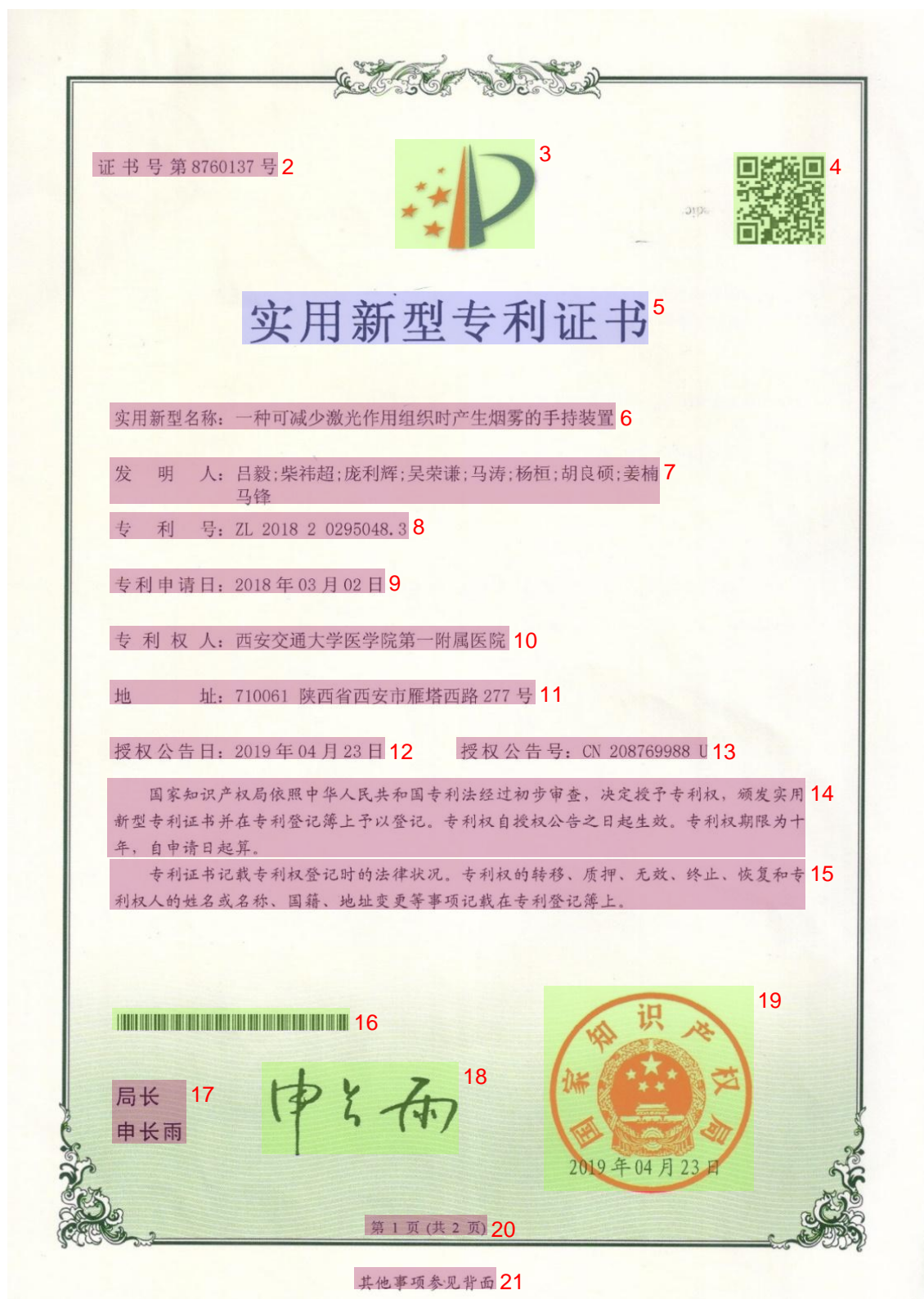申长雨¹⁸



第1页(共2页)²⁰


其他事项参阅背面²¹


11. 一种可减少激光作用组织时产生烟雾的手持式装置¹



12. 一种用于减戳卡腔镜手术的磁悬浮视频及照明系统¹

证书号第 12423019 号²

³

⁴

实用新型专利证书⁵

实用新型名称：一种用于减戳卡腔镜手术的磁悬浮视频及照明系统⁶

发明人：吕毅；陈环；马涛；王越；朱皓阳；董鼎辉⁷

专利号：ZL 2020 2 0485999.4⁸

专利申请日：2020 年 04 月 07 日⁹


专利权人：西安交通大学医学院第一附属医院¹⁰

地址：710061 陕西省西安市雁塔西路 277 号¹¹


授权公告日：2021 年 02 月 02 日¹² 授权公告号：CN 212439258 U¹³


国家知识产权局依照中华人民共和国专利法经过初步审查，决定授予专利权，颁发实用新型专利证书并在专利登记簿上予以登记。专利权自授权公告之日起生效。专利权期限为十年，自申请日起算。¹⁴

专利证书记载专利权登记时的法律状况。专利权的转移、质押、无效、终止、恢复和专利权人的姓名或名称、国籍、地址变更等事项记载在专利登记簿上。¹⁵

¹⁶

局长¹⁷
申长雨

¹⁸

¹⁹
2021 年 02 月 02 日

第 1 页 (共 2 页)²⁰

其他事项参见背面²¹

13. 一种用于内镜下消化道吻合的磁性锚定穿刺组件¹

证书号第4085195号²



发明专利证书⁵

发明名称：一种用于内镜下消化道吻合的磁性锚定穿刺组件⁶

发明人：严小鹏；吕毅；马锋；马思捷；卢强⁷

专利号：ZL 2018 1 1172739.5⁸

专利申请日：2018年10月09日⁹

专利权人：西安交通大学医学院第一附属医院¹⁰

地址：710061 陕西省西安市雁塔西路277号¹¹

授权公告日：2020年11月10日¹²

授权公告号：CN 109223129 B¹³

国家知识产权局依照中华人民共和国专利法进行审查，决定授予专利权，颁发发明专利证书并在专利登记簿上予以登记。专利权自授权公告之日起生效。专利权期限为二十年，自申请日起算。

专利证书记载专利权登记时的法律状况。专利权的转移、质押、无效、终止、恢复和专利权人的姓名或名称、国籍、地址变更等事项记载在专利登记簿上。



局长¹⁷
申长雨

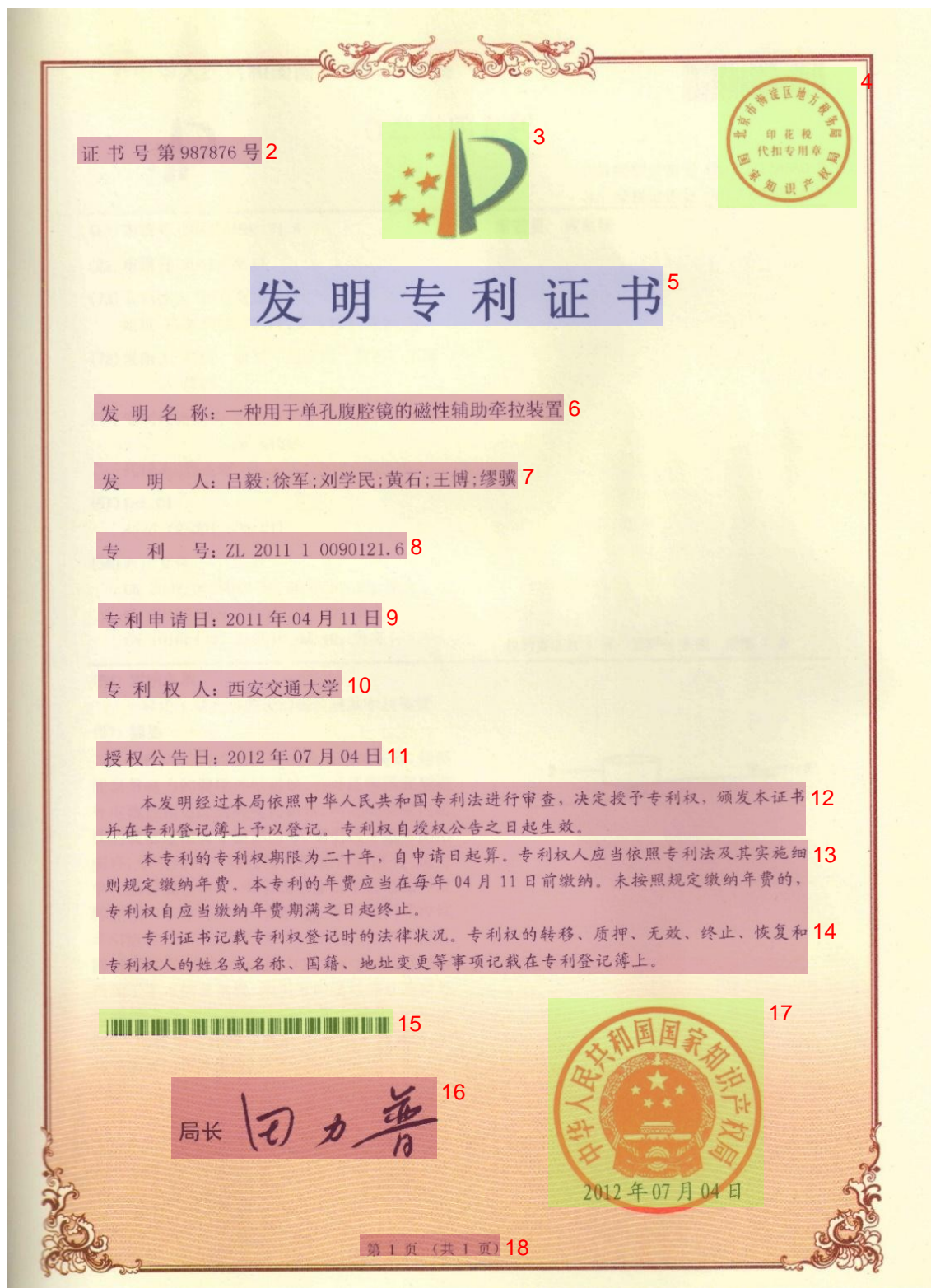
申长雨¹⁸



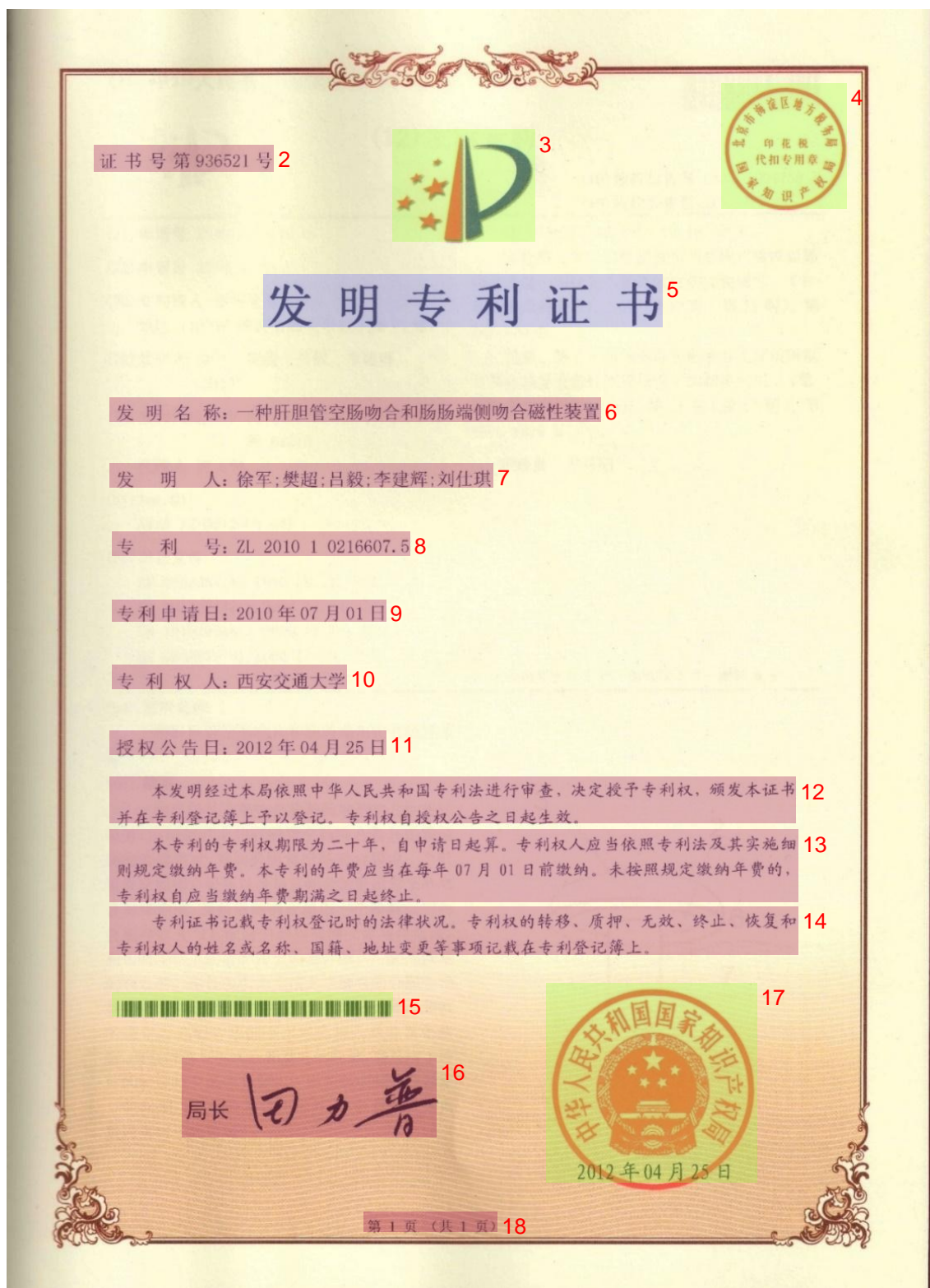
第1页(共2页)²⁰

其他事项参见背面²¹

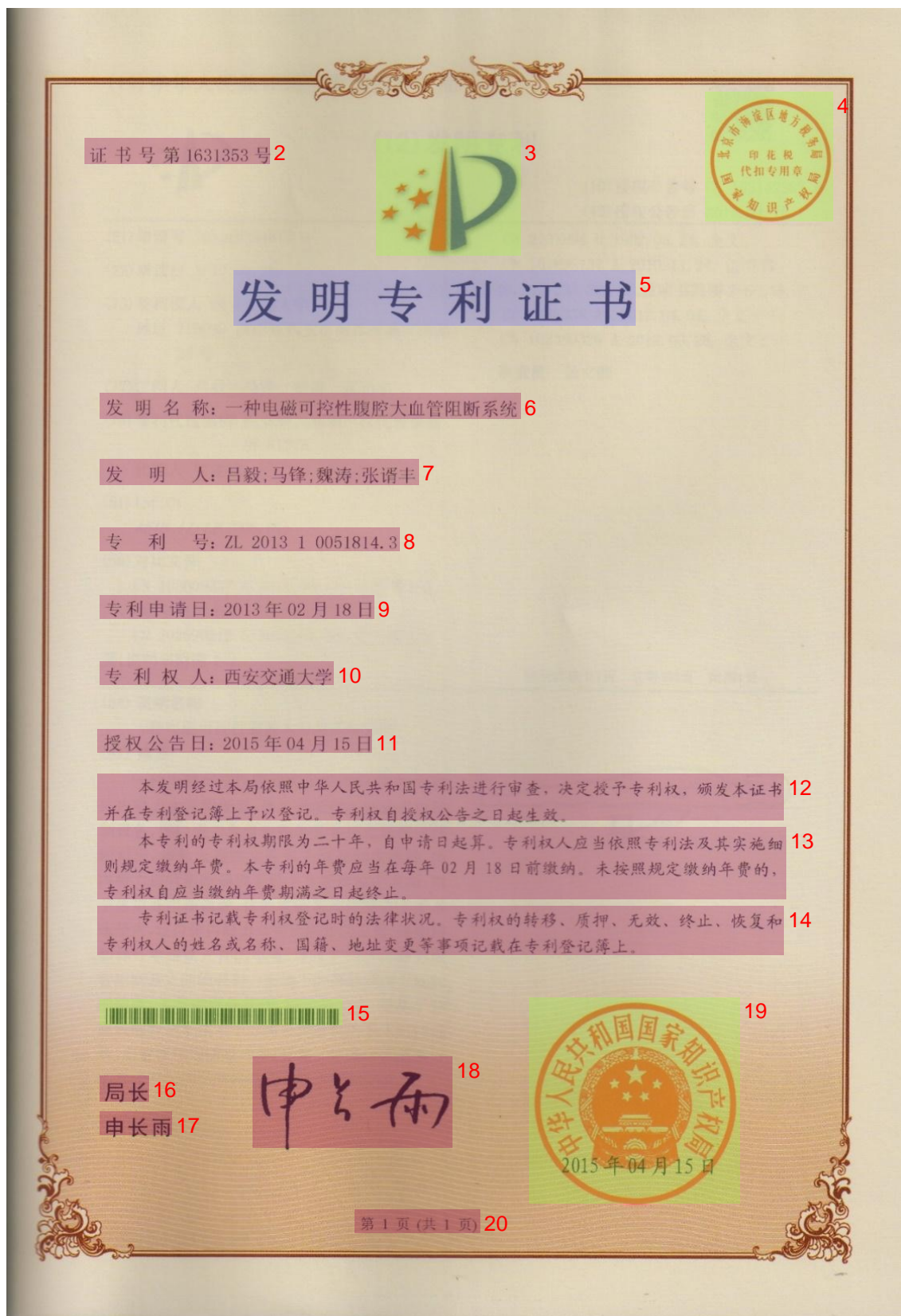
14. 一种用于单孔腹腔镜的磁性辅助牵拉装置¹



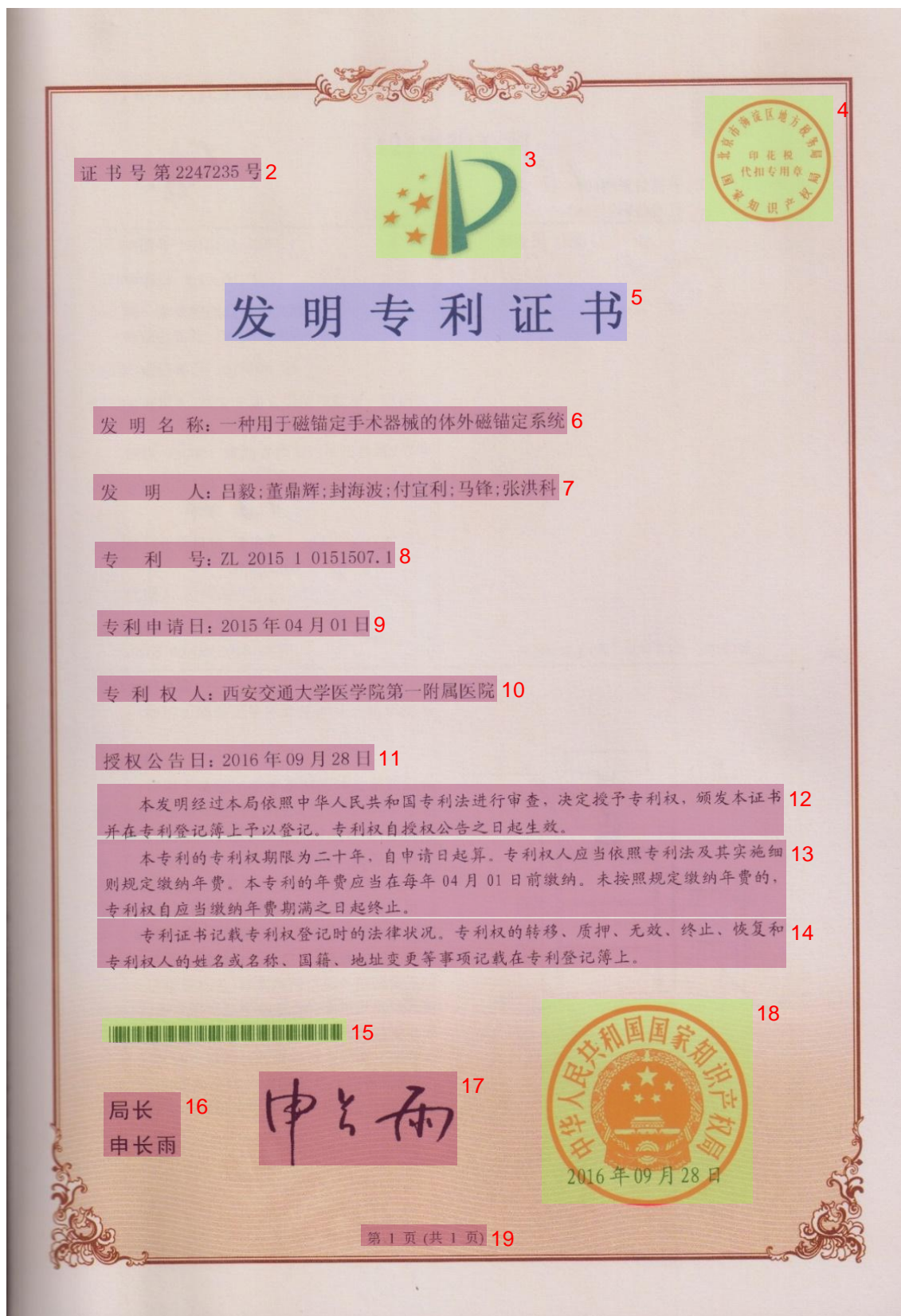
15. 一种肝胆管空肠吻合和肠肠端侧吻合磁性装置¹



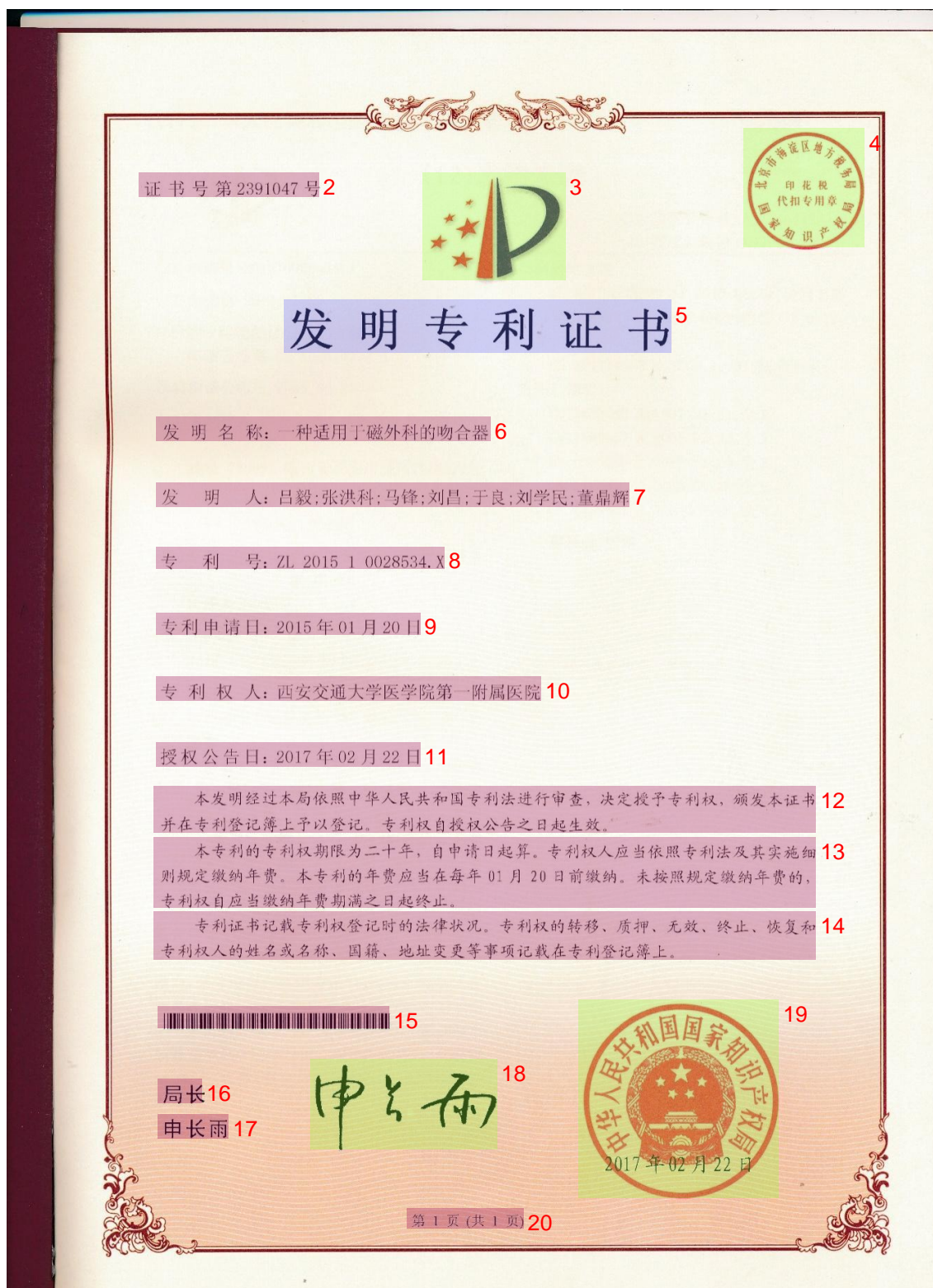
16. 一种电磁可控性腹腔大血管阻断系统¹



17. 一种用于磁锚定手术器械的体外锚定系¹





18. 一种适用于磁外科的吻合器¹



19. 一种铆钉式血管吻合装置¹

证书号第 11313297 号²

³

⁴

实用新型专利证书⁵

实用新型名称：一种铆钉式血管吻合装置⁶

发明人：马锋；吕毅；王善佩；史爱华；严小鹏；吴荣谦；李卓群
丁泓帆⁷

专利号：ZL 2019 2 2205269.4⁸

专利申请日：2019 年 12 月 11 日⁹


专利权人：西安交通大学医学院第一附属医院¹⁰

地址：710061 陕西省西安市雁塔西路 277 号¹¹


授权公告日：2020 年 08 月 25 日¹² 授权公告号：CN 211325291 U¹³


国家知识产权局依照中华人民共和国专利法经过初步审查，决定授予专利权，颁发实用新型专利证书并在专利登记簿上予以登记。专利权自授权公告之日起生效。专利权期限为十年，自申请日起算。¹⁴

专利证书记载专利权登记时的法律状况。专利权的转移、质押、无效、终止、恢复和专利权人的姓名或名称、国籍、地址变更等事项记载在专利登记簿上。¹⁵

¹⁶

局长¹⁷
申长雨

¹⁸

¹⁹
2020 年 08 月 25 日

第 1 页 (共 2 页)²⁰

其他事项参见背面²¹

20. 一种磁悬浮颈椎牵引装置¹

证书号第 11316154 号²



实用新型专利证书⁵

实用新型名称：一种磁悬浮颈椎牵引装置⁶

发明人：吕毅；薛召；史爱华；吴荣谦；马锋；汤博⁷

专利号：ZL 2019 2 2000910.0⁸

专利申请日：2019 年 11 月 19 日⁹

专利权人：西安交通大学医学院第一附属医院¹⁰


地址：710061 陕西省西安市雁塔西路 277 号¹¹

授权公告日：2020 年 08 月 25 日¹²

授权公告号：CN 211325948 U¹³

国家知识产权局依照中华人民共和国专利法经过初步审查，决定授予专利权，颁发实用新型专利证书并在专利登记簿上予以登记。专利权自授权公告之日起生效。专利权期限为十年，自申请日起算。¹⁴

专利证书记载专利权登记时的法律状况。专利权的转移、质押、无效、终止、恢复和专利权人的姓名或名称、国籍、地址变更等事项记载在专利登记簿上。¹⁵



局长¹⁷
申长雨

申长雨¹⁸



第 1 页 (共 2 页)²⁰

其他事项参见背面²¹

3) 发表的代表性文章首页:¹

1. 倡用图文外科手术记录专家共识²

倡用图文外科手术记录专家共识³ (2015·西安)

中华医学会外科学分会外科学术学组⁴

【关键词】 外科手术; 医院记录; 表格和记录管理; 图片⁵

《医疗机构病历管理规定(2013年版)》、《电子病历基本规范(卫医政发(2013)11号)》明确定义病历是指医务人员在医疗活动过程中形成的文字、符号、图表、影像、切片等资料的总和,需要规范记录,妥善保存。随着医疗信息化工作全面推进,临床病理学诊断、影像学检查、内镜镜检查治疗和介入检查治疗等报告单早已采用了图文报告形式,对临床诊疗行为规范和质量的持续改进均起到了积极作用。外科手术记录是对手术过程的客观描述,手术过程关键的照片或视频资料已被用于学术交流,但尚未被用于辅助记录手术过程。在医院高度信息化和手术室智能化的时代,用手术关键步骤实景照片辅助记录手术过程,必将大幅度增加手术记录信息含量,全面提升手术记录质量。

为了能准确、客观、详实地记录手术过程,更为了患者随访和后续治疗提供更加客观详实的临床资料,我们提倡有计划、逐步在有条件的大型医院推行使用图文手术记录,初步制定符合目前我国临床实际需要的图文手术记录规范。

年月日,在西安举行的中华医学会外科学分会外科学术学组工作会议上,就以下内容达成初步共识:

一、图文手术记录的定义⁹

图文手术记录是指使用摄影图片(手术视频截图)和文字描述共同记录手术过程的一种新型

医疗文书,使手术记录能更客观、详细地反映手术情境。图文手术记录具有丰富的手术信息含量,可使手术信息实现数字化并顺利接入医院信息系统() ,与传统手术记录相比更直观、全面,因而更具备客观性、真实性和法律效力。

二、提倡使用图文手术记录的原因¹²

目前电子病历中运行的手术记录普遍存在以下不足:() 仅用语言很难清晰描述高难度、复杂的手术全过程。() 手术记录模板大多数过于简单、陈旧,使用过程中易发生大段内容复制和粘贴,不能如实反映手术过程,或存在“千术一式”的现象。() 手术记录完成不及时,会发生对手术过程记忆不清楚而张冠李戴的情况。() 主要病变情况、与周围组织关系、复杂病变情况的描述含混甚至缺失,失去作为医疗文书的基本价值。() 由于医务人员专业知识、认知的不同,对手术记录中某些手术步骤的文字描述会发生理解偏差。() 用文字描述创新的手术、新型材料或植入性材料时,即使用大量文字描述,仍然缺乏直观感受。() 未将目前丰富的图像手术记录资源用于教学,医学生对单一文字描述的手术记录仍较难理解。() 对于有潜在风险的拯救性手术,比如肠管扭转坏死、胰胆及周围组织大块坏死、严重复合创伤等,无法详细、准确记录病情严重程度。

DOI: 10.3877/cma.j.issn.2095-3232.2015.05.003

作者单位: 710061 西安交通大学医学院第一附属医院普通外科

通讯作者: 吕毅, Email: luyi169@126.com

2. 胆道镜图文手术记录系统的研制及临床试用¹

Chinese Journal of Medical Instrumentation²

中国医疗器械杂志³
临床医学工程⁴

2017年41卷第6期⁵

文章编号: 1671-7104(2017)06-0450-03⁶

胆道镜图文手术记录系统的研制及临床试用⁷

【作者】 蔡召^{1,2,3} 胡良硕^{1,2,3} 汤博^{1,2,3} 张晓刚^{1,2,3} 吕毅^{1,2,3}⁸

1 西安交通大学第一附属医院肝胆外科, 西安市, 710061⁹

2 西安交通大学先进外科技术与工程研究所, 西安市, 710061¹⁰

3 陕西省再生医学与外科工程研究中心, 西安市, 710061¹¹

【摘 要】 目的 研制一款基于胆道镜检查的图文手术记录系统, 在临床胆道镜检查术后报告中试用。方法 在传统胆道镜检查中, 融入视频图像捕捉技术与语音识别技术, 将术中实时图像与手术步骤解说准确匹配, 快速生成并打印出个性化胆道镜图文手术记录。将该系统分别应用于病历共享、科研教学与远程交流等方面。结果 在临床32例患者胆道镜检查术后报告中试用, 明显提高了外科医生的工作效率与患者的满意度, 同时满足远程信息交互的要求。结论 胆道镜图文手术记录系统可以提高医疗服务质量, 促进手术交流和青年医师培养。¹²

【关键词】 胆道镜; 图文手术记录; 实时交互; 远程医疗; 教学¹³

【中图分类号】 R445¹⁴

【文献标志码】 A¹⁵

doi: 10.3969/j.issn.1671-7104.2017.06.016¹⁶

Development of Diagrammatic Recording System for Choledochoscope and Its Clinical Application¹⁷

【Writers】 XUE Zhao^{1,2,3}, HU Liangshuo^{1,2,3}, TANG Bo^{1,2,3}, ZHANG Xiaogang^{1,2,3}, LYU Yi^{1,2,3}¹⁸

1 Department of Hepatobiliary Surgery, First Affiliated Hospital, Xi'an Jiaotong University, Xi'an, 710061¹⁹

2 XJTU Research Institute of Advanced Surgical Technology and Engineering, Xi'an Jiaotong University, Xi'an, 710061²⁰

3 Regenerative Medicine and Surgery Engineering Research Center of Shaanxi Province, Xi'an, 710061²¹

【Abstract】 Objective To develop a diagrammatic recording system for choledochoscopy and evaluate the system with clinical application. Methods To match the real-time image and procedure illustration during choledochoscopy examination, we combined video-image capture and speech recognition technology to quickly generate personalized choledochoscopy images and texts records. The new system could be used in sharing territorial electronic medical records, telecommuting, scientific research and education, et al. Results In the clinical application of 32 patients, the choledochoscopy diagrammatic recording system could significantly improve the surgeons' working efficiency and patients' satisfaction. It could also meet the design requirement of remote information interaction. Conclusion The choledochoscopy diagrammatic recording system which is recommended could elevate the quality of medical service and promote academic exchange and training.²²

【Key words】 choledochoscope, diagrammatic recording system, real-time interactive, telemedicine, education²³

0 引言²⁴

纤维胆道镜是近年来应用较为广泛的一种集诊断和治疗为一体的医疗器械, 实现了在直视下探查肝内外胆道系统情况, 并可同时进行相应的诊疗活动^[1]。而且, 胆道镜检查记录作为患者病情及诊疗过程的客观医学资料, 应确保及时、准确、规范^[2]。然而, 目前多数医院胆道镜术后手术记录依旧采用传统的纯文字描述形式, 千篇一律, 缺乏内涵, 不利于医患关系的提升。随着医院高度信息化和数字化建设, 纯文字描述的手术记录已存在明显的不足, 亟待改善^[3]。

为了能及时、准确地记录临床胆道镜检查的过程和诊疗结果, 为患者后续治疗提供更加客观完整的病历资料, 我院肝胆外科在胆道镜检查的视频输出基础上, 提出了一种采用“图片+文字”方式记录胆道镜

诊疗过程的方法, 通过融入视频信号捕捉技术与语音识别技术, 成功研制出一款能够实时获取胆道镜检查术中图像, 自动生成胆道镜图文手术记录的胆道镜图文手术记录系统。而且, 试用中初步实现了图像共享、医师培养和远程会诊等功能。这种新颖的设计不仅填补了胆道镜图文手术记录的临床空白, 同时搭建了胆道镜诊疗的远程管理与教学平台, 进而推动医院信息化建设。该系统在临床初步试用, 取得了良好的效果。现在总结如下。

1 系统设计介绍³¹

1.1 基本思路³²

胆道镜图文手术记录系统结构如图1所示。对于常规胆道镜系统, 均已具备摄像功能, 而且我们团队已成功研制出图文手术记录软件。基于此, 我们团队设想: 如果能快速获取胆道镜检查术中的重要图像信

收稿日期: 2017-03-02²⁷

基金项目: 国家自然科学基金科学仪器专项(81127005)²⁸

通信作者: 吕毅, 教授, 博导, E-mail: lyuyi69@126.com²⁸

450³⁴

(C)1994-2022 China Academic Journal Electronic Publishing House. All rights reserved. http://www.cnki.net³⁵

3. 外科手术语音图文记录报告系统的研发及临床应用研究¹

第30卷第2期²
2016年4月³

中国医学教育技术⁴
CHINA MEDICAL EDUCATION TECHNOLOGY⁵

Vol. 30 No. 2⁶
Apr. 2016⁷

• 数字医学 •⁸

外科手术语音图文记录报告系统的⁹ 研发及临床应用研究

汤博^{1,2}, 崔晓海^{1,2,3}, 关正^{1,2,3}, 张晓刚^{1,2,3}, 吴荣谦^{1,2,3#}, 吕毅^{1,2,3#}¹⁰

西安交通大学: ¹先进外科技术与工程研究所; ²第一附属医院肝胆外科; ³陕西省再生医学与外科工程研究中心, 西安 710061¹¹

【摘要】: 外科手术语音图文记录报告系统主要由硬件系统及软件系统组合而成。硬件主要包括: 图像采集单元, 用于采集术中图像信息; 可活动臂单元, 用于安装图像采集单元调整采集角度; PC 计算机单元, 配有语音接收插口和 USB 插口, 语音接收插口与语音收发单元相连接, USB 插口与彩色打印机单元相连接; 工作站单元, 与图像采集单元连接接收其采集的图像信息; 术中监视器单元, 与工作站单元连接对其接收的图像信息进行实时显示; 无线路由器单元, 用于建立网络; 彩色打印机单元, 将 PC 计算机单元下发的打印内容进行打印; 语音收发单元, 接收语音描述以及相关解释并发送至 PC 计算机单元。软件主要是自主开发具有自主知识产权的外科手术语音图文软件。通过初步使用, 显示该系统既可实现术中实时图片采集, 又可配有主刀操作步骤说明, 通过软硬件处理后生成手术图文报告。¹²

【关键词】: 外科手术; 图文记录; 语音¹³

【中图分类号】: G434; R-058 **【文献标志码】**: A **【文章编号】**: 1004-5287(2016)02-0194-04¹⁴

【DOI】: 10.13566/j.cnki.cmet.cn61-1317/g4.201602023¹⁵

Research and development of intraoperative medical images and texts recording report system and its clinical application¹⁶

Tang Bo^{1,2}, Cui Xiaohai^{1,2,3}, Guan Zheng^{1,2,3}, Zhang Xiaogang^{1,2,3}, Wu Rongqian^{1,2,3#}, Lü Yi^{1,2,3#}¹⁷
¹Research Institute of Advanced Surgical Technology and Engineering; ²Department of¹⁸
Hepatobiliary Surgery, the First Affiliated Hospital of Xi'an Jiaotong University; ³Regenerative Medicine¹⁹
and Surgery Engineering Research Center of Shaanxi Province, Xi'an 710061, China²⁰

【Abstract】: The recording report system for intraoperative medical images and texts mainly consists of hardware and software systems. The hardware system includes the image-capturing unit, the jointed arm unit, the PC computer unit, the workstation unit, the intraoperative monitor unit, the wireless router unit, the color-printing unit, and the voice transmitting-receiving unit. The image-capturing unit is in charge of shooting images during each surgery. The jointed arm unit installs the image-capturing unit and adjusts the angles to take pictures. The PC computer unit has sockets for audio information receiving and USB. The audio information-receiving socket is connected with the audio information receiving and transmitting unit, and the USB socket is connected with a color printer. The workstation unit is linked with the image-shooting unit to receive images information. The monitor unit, joined with the workstation unit, shows real-time image information received from the workstation. The wireless router unit creates the network. The color-printing unit prints the files which the PC computer issues. The voice transmitting-receiving unit receives and transmits the voice descriptions and explanations to the PC²¹

基金项目: 国家自然科学基金科学仪器项目(81127005/H0322); 教育部“创新团队发展计划”(IRT1279)²²

收稿日期: 2016-03-01²³

作者简介: 汤博(1989-), 男, 陕西宝鸡人, 硕士研究生在读, 主要研究方向: 医工结合外科辅助器械研发。²⁴

通信作者: 吴荣谦(1971-), 男, 武汉人, 教授, 博士研究生导师, 博士, 主要研究方向: 重症医学研究、外科技术创新及医工结合²⁵
方面的研究。电话: 18629053941; E-mail: rwugmail@163.com²⁶

吕毅(1963-), 男, 西安人, 教授, 博士研究生导师, 博士, 主要研究方向: 肝移植临床研究、外科技术创新及应用。²⁷
电话: 13991200581; E-mail: luyi169@126.com²⁸

注: #同为通信作者²⁹

4. 外科手术语音图文工作站——探索数字化精准教学新模式¹

DOI:10.19347/j.cnki.2096-1413.2016.11.002²

临床医学研究与实践 2016年6月15日 第1卷第11期³

·研究原著·⁴

外科手术语音图文工作站⁵ ——探索数字化精准教学新模式

吕毅^{1,2,3}, 汤博^{1,2}, 薛召³, 史爱华^{1,2}, 吴荣谦^{1,2}⁶

(1. 西安交通大学先进外科技术与工程研究所, 陕西 西安, 710061; 2. 陕西省再生医学与外科工程研究中心,⁷

陕西 西安, 710061; 3. 西安交通大学第一附属医院, 陕西 西安, 710061)⁸

摘要: 新型教学设备研发及优质的教学方法是培养现代外科医生的新途径。外科手术图文记录全面实现了主刀医生在术中对其硬件及软件平台进行自主控制, 根据术中需求, 采用语音控制或智能控制的方法精确抓取图像和语音信息, 及时生成“图文并茂”的手术报告。每份手术图文报告都可作为精品教学资源, 便于年轻医师学习和理解。外科手术图文报告不仅可以大大缩短年轻医师的学习曲线, 提高学习积极性, 而且可以提高医疗服务质量, 对促进医师相互之间的学术交流和病例讨论意义重大。⁹

关键词: 创新; 教学; 手术图文报告¹⁰

中图分类号: R612¹¹ **文献标志码:** A¹² **文章编号:** 2096-1413(2016)11-0006-03¹³

Intraoperative medical images and texts recording report: explore the new models of digital precision teaching¹⁴

LV Yi^{1,2,3}, TANG Bo^{1,2}, XUE Zhao³, SHI Ai-hua^{1,2}, WU Rong-qian^{1,2}¹⁵

(1. Research Institute of Advanced Surgical Technology and Engineering, Xi'an Jiaotong University, Xi'an 710061; 2. Regenerative Medicine and Surgery Engineering Research Center of Shaanxi Province, Xi'an 710061; 3. Department of Hepatobiliary Surgery, the First Affiliated Hospital of Xi'an Jiaotong University, Xi'an 710061, China)¹⁶

ABSTRACT: New teaching equipment research and development and quality of teaching methods are important way to cultivate modern surgeons. Through intraoperative medical images and texts recording report, the surgeons can independently control the hardware and software platforms in operation process in accordance with the requirements of surgical procedure, and take voice control or intelligent control method precise grasping image and voice information, timely generation "illustrated" operation reports, and each operation picture and text report are excellent courseware. Intraoperative medical images and texts recording report not only can greatly shorten the learning curve of young doctors and improve the learning efficiency of young doctors, but also can improve the quality of medical service and is of important significance for academic exchanges and medical record discussions between doctors.¹⁷

KEYWORDS: innovation; teaching; intraoperative medical images and texts recording report¹⁸

随着医疗信息技术的不断发展, 临床病理学诊断、影像学检查、内镜镜检查治疗和介入检查治疗等报告单早已采用了图文报告形式, 且可整合到医院信息系统中。这种图文报告不仅有助于医患沟通和医师诊断, 还可减少医疗资源的浪费。外科手术记录作为临床最为重要的医疗文书之一, 是接诊医师快速了解病情的重要途径, 因此, 详细、准确、客观的手术记录尤为重要。但传统外科手术记录单纯采用文字描述的形式, 缺乏重要的图片信息, 很难清晰地反映手术全过程。此外, 由于手术工作者时间紧迫, 手术记录常出现大量复制现象, 描述不直观, 造成手术记录缺乏客观性、及时性和法律效力, “千术一式”的现象普遍存在。纯文字的手术记录亦成为医疗文书全面信息化、数字化的“最后死角”。¹⁹学会外科学术学组会议上也发起了“倡用图文手术记录专家共识”, 得到与会专家的积极响应²¹。总之, 外科手术图文报告能够明显提高年轻医生的学习兴趣, 强化对手术的理解, 在培养年轻外科医生、临床教学及学术交流等方面意义重大。

1 设备研发²²

立足创新性从临床迫切的需求出发, 加之团队长期立足于“理、工、医”多学科交叉的基础, 本研究在 10 余年工作经验积累基础上, 又经过 3 年时间的研制, 首次理清了外科手术语音图文记录工作的新模式, 其核心是汇集现代计算机硬件技术、软件技术、语音识别、电子、光学、图像处理等高新技术于一体²³。我们团队在世界上首次提出图文手术记录的定义及规范, 主持编写并公开发表了中华医学会外科学分会的《倡用图文外科手术记录专家共识》, 为研发语音图文手术记录系统奠定了理论基础和行业支持保证, 最终成功研制出一款应用外科手术语音图文系统。其工作路线如图 1 所示。²⁴

较传统外科手术记录, 语音图文系统更加可靠、便捷。这不仅有助于医师教学、交流和自身业务的提高, 也可用于患者的术后复诊、转诊等, 利于诊疗资料的留存²⁴。

作者简介: 吕毅 (1963-), 男, 陕西西安人, 教授, 博士研究生导师, 博士。研究方向: 肝移植临床研究, 外科技术创新及应用。基金项目: 国家自然科学基金科学仪器项目 (No. 81127005/110322); 教育部“创新团队发展计划” (No. IRT1279)。



5. Adhesive anastomosis for organ transplantation ¹

Research Materials 18 (2022) 261–268 ²

Contents lists available at ScienceDirect ⁵

Bioactive Materials ⁶

journal homepage: www.elsevier.com/locate/jbmat ⁷



Adhesive anastomosis for organ transplantation ⁹

Kang Liu ^{a,1}, Hang Yang ^{b,1,1}, Gaobo Huang ^{a,1}, Aihua Shi ^a, Qiang Lu ^a, Shanpei Wang ^a,
Wei Qiao ^a, Haohua Wang ^a, Mengyun Ke ^a, Hongfan Ding ^a, Tao Li ^a, Yanchao Zhang ^a,
Jiawei Yu ^a, Bingyi Ren ^a, Rongfeng Wang ^a, Kailing Wang ^a, Hui Feng ^a, Zhigang Suo ^{c,***},
Jingda Tang ^{b,*,**}, Yi Lv ^{b,†} ¹¹

^a National Local Joint Engineering Research Center for Precision Surgery and Regenerative Medicine, Department of Hepatobiliary Surgery, First Affiliated Hospital of Yanbian University, Qian, 133001, Shanxi, P.R. China ¹²

^b State Key Lab for Strength and Vibration of Mechanical Structures, International Center for Applied Mechanics, Department of Engineering Mechanics, Tsinghua University, Beijing, 100084, China

^c John A. Paulson School of Engineering and Applied Science, MIT Institute for Data Science and Technology, Harvard University, Cambridge, MA, 02138, USA

^{*} Hepatobiliary Surgery Department, Shanxi Provincial People's Hospital, Qian, 133001, Shanxi, P.R. China

ARTICLE INFO ¹³

Keywords: ¹⁴
Surgery ¹⁵
Wound ¹⁶
Adhesive ¹⁷
Anastomosis ¹⁸
Time ¹⁹

ABSTRACT ²⁰

The recent development of tough tissue adhesives has stimulated intense interests among material scientists and medical doctors. However, these adhesives have seldom been used in clinically demanding surgeries. Here we demonstrate adhesive anastomosis in organ transplantation. Anastomosis is commonly conducted by device sutures and takes a long time, during which all the vessels are occluded. Prolonged occlusion may damage organs and even cause death. We formulate a tough, biocompatible, bioabsorbable adhesive that can sustain tissue tension and prevent thrombosis. We expose the endothelial surface of vessels onto a gelatin, press two endothelial surfaces in the adhesive using a pair of magnetic rings, and repress the blood stream immediately. The time for adhesive anastomosis is shortened compared to the time for sutured anastomosis. We have achieved adhesive anastomosis of a great vein in transplanting the liver of a pig. After the surgery, the adhesive is absorbed, the vein heals, and the pig lives for over one month. ²¹

1. Introduction ²²

Efforts have long been made to replace sutures with adhesives in surgical procedures, including wound dressing [1,2], hemostasis [3,4], gastrointestinal surgeries [5], and microvascular anastomosis [6]. Adhesives have also been applied for clinically demanding surgeries such as nerve anastomosis and heart-lung transplantations for decades. In nerve anastomosis, the adhesives are applied on the injured neurons with mechanical fixation [7], or work as the tissue scaffold [8,9] to help the neuron regeneration. While the nerve anastomosis does not require a strong adhesion, because the anastomosed nerve will not sustain a large mechanical load such as blood pressure [4,10]. In heart-lung transplantations, the vessels are always anastomosed by suture firstly, and

then the adhesive is applied on the periphery of the vessel [11–13]. The adhesives are always used to reduce blood loss and help the suture area to regenerate, which cannot anastomose the vessels together directly due to their low adhesion strength [14–16]. ²³

Adhesive anastomosis, however, has yet been demonstrated for organ transplantation. Since 1954, millions of livers have been saved by transplanting organs, including kidneys, livers, hearts, lungs, pancreas, and bowels [17–19]. To transplant an organ, all the affiliated main vessels of the recipient are occluded. The surgeon clamps the vessels, pulls the two ends of the vessels together by threads, and sews a circle of stitches (Fig. 1A) [20,21]. The stitches must be dense enough to prevent bleeding, so that the vessels must be clamped for a long time. During a transplantation of liver, for example, three great veins are occluded,

Peer review under responsibility of Elsevier Communications Co., Ltd.

[†] Corresponding author.

^{**} Corresponding author.

^{***} Corresponding author.

E-mail addresses: yanghang@163.com (H. Yang), tangjingda@tsinghua.edu.cn (J. Tang), lv-yi@pku.edu.cn (Y. Lv).

[†] These authors contributed equally to this work.

<https://doi.org/10.1016/j.jbmat.2021.11.001> ²⁶

Received 26 August 2021; Received in revised form 19 October 2021; Accepted 1 November 2021 ²⁷

Available online 18 November 2021

2462-1983/© 2021 The Authors. Publishing services by Elsevier B.V. on behalf of Elsevier Communications Co., Ltd. This is an open access article under the CC ²⁹

BY-NC-ND 4.0 International license.

6. SRY is a Key Mediator of Sexual Dimorphism in Hepatic Ischemia/Reperfusion Injury ¹

ORIGINAL ARTICLE ²

SRY is a Key Mediator of Sexual Dimorphism in Hepatic Ischemia/Reperfusion Injury ³

Jian Deng, MD, ^{††} Meng-Yan Ke, PhD, ^{††} Xiao-Ning Wu, MD, ^{††} Hong-Fan Ding, MD, ^{††} Li-Na Zhang, MD, [§] ⁴
Feng Ma, MD, ^{††} Xue-Miao Liu, MD, ^{††} Bo Wang, MD, ^{††} Jian-Lin Liu, MD, ^{††} Shao-Yang Lu, MD, ^{††} ⁵
Rongqian Wu, MD, PhD, ^{††} Timothy M. Pivvli, MD, MPH, PhD, [¶] Yi-Lin, MD, PhD, ^{***} ⁶
and Xu-Feng Zhang, MD, PhD, ^{†††} ⁷

Objectives: To identify the role and mechanism of a male specific gene, SRY, in I/R-induced hepatic injury. ⁸
Background: Males are more vulnerable to I/R injury than females. However, the mechanism of these sex-based differences remains poorly defined. ⁹
Methods: Clinicopathologic data of patients who underwent hepatic resection were identified from an international multi-institutional database. Liver specific SRY TG mice were generated, and subjected to I/R insult with their littermate WT controls in vivo. In vitro experiments were performed by treating primary hepatocytes from TG and WT mice with hypoxia/reoxygenation stimulation. ¹⁰
Results: Clinical data showed that postoperative morbidity/mortality level, incidence of overall mortality and liver failure were markedly higher among 1267 male versus 588 female patients who underwent hepatic resection. SRY was differentially upregulated during hepatic I/R injury. Overexpression of SRY in male TG mice and ectopic expression of SRY in female TG mice exacerbated liver I/R injury compared with WT or transfected by increased

inflammatory reaction, oxidative stress and cell death in vivo and in vitro. Mechanistically, SRY interacts with Glycogen synthase kinase-3 β (GSK-3 β) and β -catenin, and promotes phosphorylation and degradation of β -catenin, leading to suppression of the downstream FOXO, and activation of NF- κ B and TLR4 signaling. Furthermore, activation of β -catenin almost completely reversed the SRY overexpression-mediated exacerbation of hepatic I/R damage. **Conclusions:** SRY is a novel hepatic I/R mediator that promotes hepatic inflammatory reaction, oxidative stress and cell necrosis via inhibiting Wnt/ β -catenin signaling, which accounts for the sex-based disparity in hepatic I/R injuries. ¹¹

Keywords: β -catenin, sex, hepatic ischemia/reperfusion injury, sex-determination region on Y chromosome ¹²

(Ann Surg 2020;xx:xxx-xxx) ¹³

From the [†]Department of Hepatobiliary Surgery and Institute of Advanced Surgical Technology and Engineering, The First Affiliated Hospital of Xi'an Jiaotong University, Xi'an, Shaanxi Province, China; ^{††}National Local Joint Engineering Research Center for Precision Surgery & Regenerative Medicine, Xi'an Jiaotong University, Xi'an, Shaanxi Province, China; [‡]Department of Vascular Surgery, The First Affiliated Hospital of Xi'an Jiaotong University, Xi'an, Shaanxi Province, China; [§]Department of Pharmacy, the Second Affiliated Hospital of Xi'an Jiaotong University, Xi'an, Shaanxi Province, China; [¶]Department of Surgery, Division of Surgical Oncology, The Ohio State University Wexner Medical Center and James Comprehensive Cancer Center, Columbus, Ohio. ¹⁴
E.D., M.Y.K., and X.N.W. contributed equally to this work. ¹⁵
The abstract has been presented to the Liver Meeting of American Association for the Study of Liver Diseases, Washington DC, USA, November, 2017, and The American College of Surgeons Clinical Congress, Boston, Massachusetts, USA, October, 2018. ¹⁶
This study was supported by the National Natural Science Foundation of China (No. 81373282, 81700546), and the Clinical Research Award of the First Affiliated Hospital of Xi'an Jiaotong University of China (No. XJTU1AF-CRF-2017-08).

The authors report no conflicts of interest. ¹⁹
Authors' contribution to the manuscript: Jian Deng made substantial contributions to conception and design, patient data analysis, in vivo and in vitro studies performance, participated in drafting the article and reviewing it critically for important intellectual content, and gave final approval of the version to be published. Xiao-Ning Wu made substantial contributions to conception and design, patient data analysis, in vivo and in vitro studies performance, participated in drafting the article and reviewing it critically for important intellectual content, and gave final approval of the version to be published. Meng-Yan Ke made substantial contributions to conception and design, patient data analysis, in vivo and in vitro studies performance, participated in drafting the article and reviewing it critically for important intellectual content, and gave final approval of the version to be published. Hong-Fan Ding made substantial contributions to conception and design, in vivo and in vitro studies performance, participated in drafting the article and reviewing it critically for important intellectual content, and gave final approval of the version to be published. Li-Na Zhang made substantial contributions to conception and design, in vivo and in vitro studies performance, participated in drafting the article and reviewing it critically for

important intellectual content, and gave final approval of the version to be published. Feng Ma made substantial contributions to conception and design, in vivo and in vitro studies performance, participated in drafting the article and reviewing it critically for important intellectual content, and gave final approval of the version to be published. Xue-Miao Liu made substantial contributions to conception and design, in vivo and in vitro studies performance, participated in drafting the article and reviewing it critically for important intellectual content, and gave final approval of the version to be published. Bo Wang made substantial contributions to conception and design, in vivo and in vitro studies performance, participated in drafting the article and reviewing it critically for important intellectual content, and gave final approval of the version to be published. Jian-Lin Liu made substantial contributions to conception and design, in vivo and in vitro studies performance, participated in drafting the article and reviewing it critically for important intellectual content, and gave final approval of the version to be published. Shao-Yang Lu made substantial contributions to conception and design, in vivo and in vitro studies performance, participated in drafting the article and reviewing it critically for important intellectual content, and gave final approval of the version to be published. Rongqian Wu made substantial contributions to conception and design, in vivo and in vitro studies performance, participated in drafting the article and reviewing it critically for important intellectual content, and gave final approval of the version to be published. Timothy M. Pivvli made substantial contributions to conception and design, and analysis and interpretation of data, participated in drafting the article and reviewing it critically for important intellectual content, and gave final approval of the version to be published. Yi-Lin made substantial contributions to conception and design, and analysis and interpretation of data, participated in drafting the article and reviewing it critically for important intellectual content, and gave final approval of the version to be published. Xu-Feng Zhang made substantial contributions to conception and design, and analysis and interpretation of data, participated in drafting the article and reviewing it critically for important intellectual content, and gave final approval of the version to be published. ²⁰

Supplemental digital content is available for this article. Direct URL citations appear in the printed text and are provided in the HTML and PDF versions of this article on the journal's Web site (www.annalsurgery.com). ²²

Copyright © 2020 Wolters Kluwer Health | All rights reserved. ²³
DOI: 10.1097/SLA.0000000000002425 ²⁴
25

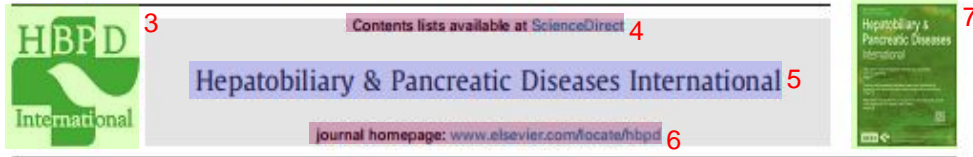
Annals of Surgery • Volume XX, Number XX, Month 2020 ²⁶

www.annalsurgery.com | 1 ²⁷

Copyright © 2020 Wolters Kluwer Health, Inc. Unauthorized reproduction of this article is prohibited. ²⁸

7. Expert consensus on the application of the magnetic anchoring and traction technique in thoracoscopic and laparoscopic surgery

Hepatobiliary & Pancreatic Diseases International 21 (2022) 7–9



Practice Guidelines

Expert consensus on the application of the magnetic anchoring and traction technique in thoracoscopic and laparoscopic surgery

Ji-Gang Bai^{a,b,c}, Yue Wang^{a,b,c}, Yong Zhang^{d,*}, Yi Lv^{a,b,c,*}, Scientific Committee of the Third International Conference of Magnetic Surgery

^aDepartment of Hepatobiliary Surgery, Institute of Advanced Surgical Technology and Engineering, The First Affiliated Hospital of Xi'an Jiaotong University, Xi'an 710061, China
^bNational Local Joint Engineering Research Center for Precision Surgery & Regenerative Medicine, The First Affiliated Hospital of Xi'an Jiaotong University, Xi'an 710061, China
^cShaanxi Provincial Center for Regenerative Medicine and Surgical Engineering, The First Affiliated Hospital of Xi'an Jiaotong University, Xi'an 710061, China
^dDepartment of Thoracic Surgery, The First Affiliated Hospital of Xi'an Jiaotong University, Xi'an 710061, China

Introduction

The mutual interference between surgical instruments in thoracoscopic and laparoscopic surgery and the effective exposure of the surgical field are important factors affecting surgical operability [1]. Magnetic anchoring and traction is one of the core techniques of magnetic surgery, which uses magnetic materials to generate force through indirect contact to achieve traction exposure of the target organs [2] (Fig. 1). The magnetic anchoring and traction system comprises an internal and an external magnetic component. The external magnetic component is usually a permanent magnet, and the internal magnetic component includes an internal magnet and a tissue clip. This system requires fewer trocars, reduces surgical trauma, and improves surgical operability [3]. At present, the magnetic anchoring and traction technique has been applied in many fields including general surgery [3–10], gynecology [10,11], urology [12–14], and thoracic surgery [15]. We formed the following consensus on the indications, contraindications, surgical skills, notes, and complication management for the clinical application of the magnetic anchoring and traction technique.

Indications and contraindications

Indications

Currently, thoracic and laparoscopic surgery requires traction to ensure that the exposure of the surgical field is suitable for the application of the magnetic anchoring and traction technique, such as in laparoscopic cholecystectomy [3,5–8], appendectomy [9,11], ovarian cystectomy [11], hysterectomy [10], nephrectomy and prostatectomy [12–14], thoracoscopic lobectomy [15], and esophagectomy. Suitable diseases include: (A) benign cholecystitis, gallbladder polyps and other benign gallbladder lesions; (B)

appendicitis; (C) benign gynecological diseases, including ovarian cysts, fibroids and ectopic pregnancy; (D) renal tumors, prostate cancer; (E) benign and malignant pulmonary nodules; (F) early and middle stage esophageal cancer, including squamous cell carcinoma, adenocarcinoma, etc.

Contraindications

- (1) Serious dysfunctions of vital organs such as the heart, lung, kidney and brain, leading to the patients unable to tolerate the surgery, in which existing methods of thoracic and laparoscopic surgery are also contraindicated [3].
- (2) Excessive obesity and thickness of the chest and abdominal wall result in the magnetic anchoring force being unable to achieve effective traction [3,7]. However, the specific upper limit of body mass index (BMI) is uncertain. The maximum of BMI in the literature was 67.7 kg/m² [16].
- (3) Patients with magnetic implant in the body [3]. This would be a relative contraindication. For example, for patients with pacemaker, we are able to perform abdominal procedures (such as prostatectomy) because there is a sufficient distance to assure that the magnet would not impact on the pacemaker, so this is not a contraindication for abdominal surgery. But for thoracoscopic surgery, this may be a contraindication.

Application routine

Preoperative evaluation and preparation

- (1) According to the factors such as the thickness of the thoraco-abdominal wall and the traction force required to pull the target organ, surgeons need to evaluate the range of magnetic force required for effective anchoring and pulling, and select the appropriate external and internal magnetic components [17,18].
- (2) Preoperative instrument sterilization. In order to prevent corrosion of the magnetic instruments and weakening of the magnetic force, the method of strong corrosion and high temperature should not be used for the sterilization of magnetic instru-

* Corresponding authors.
E-mail addresses: zhangyongyang05@163.com (Y. Zhang), luyi169@126.com (Y. Lv).

8. Magnetic hyperthermia induces effective and genuine immunogenic tumor cell death with respect to exogenous heating

Journal of Materials Chemistry B

ROYAL SOCIETY OF CHEMISTRY

PAPER

View Article Online

Check for updates

Magnetic hyperthermia induces effective and genuine immunogenic tumor cell death with respect to exogenous heating†

Bin Yan,¹ Chen Liu,² Siyao Wang,² Huiang Li,³ Ju Jiao,¹ Wee Siang Vincent Lee,⁴ Song Zhang,⁵ Yayi Hou,⁶ Yuzhu Hou,⁷ Xiaowei Ma,⁸ Haiming Fan,⁹ Yi Lv¹⁰ and Xiaoli Liu^{10*}

Immunogenic cell death (ICD) can improve the therapeutic effects of cancer immunotherapy by initiating adaptive immune responses. Unlike the exogenous hyperthermia modality in clinics, magnetic hyperthermia (MH) is characterized by an iron oxide nano-agent acting as a heating source and the effects induced by heating acting at the intracellular region. However, the immunological effects of endogenous heating generated during MH and exogenous heating and the difference in damage-associated molecular pattern (DAMP) emissions correlating with the ICD are unclear; whether MH elicits genuine ICD remains unknown. Herein, we have identified 33 distinct DAMP correlates of ICD induced by intracellular MH, and found that only heat shock proteins 70/90 were expressed after water bath heating (exogenous hyperthermia) in human triple-negative breast cancer (TNBC) MDA-MB-232 cells, murine TNBC 4T1 cells, and surgically resected specimens of ductal breast cancer from patients. In vivo vaccination assays were performed in immunocompetent BALB/c mice. The results demonstrated that MH with endogenous heating could stimulate the genuine ICD on 4T1 cells and achieved optimal therapeutic effects on 4T1 tumors, whereas exogenous heating under the same conditions failed to elicit these effects. These findings with regard to the MH-induced genuine ICD with high efficiency are critical for the development of safe and effective therapeutics to amplify the therapeutic responses of cancer immunotherapy.

Received 8th May 2022, Accepted 16th June 2022
DOI: 10.1039/d2em00048f

www.rsc.org/materials-b

Introduction

Cancer immunotherapy aims to boost the immune system of cancer patients to destroy tumor cells and prevent their recurrence without damaging normal cells.^{1–3} The activation of cytotoxic T lymphocytes has been proved as a key way in cancer immunotherapy, which starts from antigen generation to antigen presentation, activation, expansion, and differentiation of antigen-specific lymphocytes, and ends with the elimination of tumors.^{4–6} To a large extent, the occurrence of this process is determined by immunogenicity elicited by dying malignant cells, named ‘immunogenic cell death (ICD)’. The extent of ICD depends greatly on the antigenicity of malignant cells and their capacity to generate adjuvant signals.^{6,10} As the immune system perceives cell death as immunogenic, it could positively influence the disease outcome of cancer patients treated with ICD inducers.^{11–13} Thus, the ICD has profound clinical and therapeutic implications.¹⁴ The improvement of immunogenicity plus boosting of antigen/adjuvant generation is a critical step for therapeutic strategies that require antigen-specific lymphocyte stimulation.^{15,16}

* Laboratory of Resource Biology and Biotechnology in Eastern China, Ministry of Education, Provincial Key Laboratory of Biotechnology of Shanghai Province, Northeast University, Xi'an, Shaanxi 710009, China. E-mail: liuxiaoli@neu.edu.cn

¹ Department of Stomach Medicine, The Third Affiliated Hospital of Jin Jiao University, 480 Tianhe Road, Guangzhou, Guangdong 510630, China

² Department of Materials Science and Engineering, National University of Singapore, 117573, Singapore

³ College of Life Sciences, Nankai University, Tianjin 300071, China

⁴ The State Key Laboratory of Pharmaceutical Biotechnology, Division of Biotechnology, Medical School, Jiangsu Key Laboratory of Molecular Medicine, Nanjing University, Nanjing 210093, China

⁵ Department of Pathogenic Microbiology and Immunology, School of Basic Medical Science, Xi'an Jiaotong University, Xi'an, Shaanxi 710061, China

⁶ National Center for Veterinary Drug Safety Evaluation, College of Veterinary Medicine, China Agricultural University, Beijing 100193, China

⁷ Institute of Regenerative and Reconstructive Medicine, MD-Y Institute, First Affiliated Hospital of Xi'an Jiaotong University, Xi'an, Shaanxi 710008, China

⁸ National Local Joint Engineering Research Center for Precision Surgery & Regenerative Medicine, Shaanxi Provincial Center for Regenerative Medicine and Tissue Engineering, First Affiliated Hospital of Xi'an Jiaotong University, Xi'an, Shaanxi 710063, China

† Electronic supplementary information (ESI) available: See DOI: 10.1039/d2em00048f

‡ These authors contributed equally to this work.

S364 | *Material Chemistry B*, 2022, 10, 3364–3374

This journal is © The Royal Society of Chemistry 2022

9. The role of magnetic anchoring and traction technique in thoracoscopic lymphadenectomy along the left recurrent laryngeal nerve

Surgical Endoscopy (2022) 36:3653–3662
<https://doi.org/10.1007/s00464-022-09052-w>

NEW TECHNOLOGY

The role of magnetic anchoring and traction technique in thoracoscopic lymphadenectomy along the left recurrent laryngeal nerve

Junkai Fu¹ · Yunhao Li¹ · Ziyi Wang^{1,2} · Yuan Cheng^{1,2} · Hanzhang Chen¹ · Xin Sun¹ · Boxiang Zhang¹ · Ziyang Peng³ · Wenwen Chen^{1,2} · Kongkai Qian^{1,2} · Aihua Shi² · Xiaopeng Yan^{1,4} · Huchua Wang² · Fang Ma² · Yi Lu^{1,4} · Yong Zhang^{1,4}

Received: 5 July 2021 / Accepted: 11 January 2022 / Published online: 26 January 2022
© The Author(s), under exclusive license to Springer Science+Business Media, LLC, part of Springer Nature 2022

Abstract

Background Dissecting lymph nodes along the left recurrent laryngeal nerve (LRLN) is the most challenging step in thoracoscopic-assisted esophagectomy. To retract the proximal esophagus in the existing lymphadenectomy methods, either a special trocar is required to insert and take out endoscopic instruments or thoracic punctures are needed to externally retract the esophageal loop. Therefore, advanced skills for esophageal traction are important to facilitate the LRLN lymphadenectomy and to reduce the incidence of trauma to the chest wall. Herein, we present the magnetic anchoring and traction technique, a novel method for LRLN lymphadenectomy during thoracoscopic esophagectomy.

Methods The magnetic anchoring traction system was successfully used to retract the upper thoracic esophagus and to help expose the upper mediastinum in 10 cases of thoracoscopic-assisted esophagectomy. When the external magnet was moved outside of body, the internal magnet was coupled with a magnetic force to pull the proximal esophagus to the appropriate direction, which helped to expose the LRLN and adjacent lymph nodes. The lymph nodes adjacent to the LRLN could then be dissected completely without any damage to the nerve.

Results In all surgeries, the LRLN and adjacent lymph nodes were well visualized, and the number of trocars used to pass endoscopic instruments for retraction of the proximal esophagus or the number of thoracic punctures for external traction of the esophagus during the surgery were reduced.

Conclusions In thoracoscopic-assisted esophagectomy, the magnetic anchoring and traction technique can improve the exposure of the LRLN, facilitate LRLN lymphadenectomy, and reduce chest wall trauma.

Keywords Magnetic anchoring and traction technique · Thoracoscopic esophagectomy · Lymphadenectomy · Left recurrent laryngeal nerve

Junkai Fu and Yunhao Li have contributed equally to this work.

✉ Yong Zhang
zhangyongyang020@163.com

¹ Department of Thoracic Surgery, The First Affiliated Hospital of Xi'an Jiaotong University, Xi'an 710061, China

² Xi'an Jiaotong University Health Science Center, Xi'an, China

³ National Local Joint Engineering Research Center for Precision Surgery & Regenerative Medicine, The First Affiliated Hospital of Xi'an Jiaotong University, Xi'an, China

⁴ Department of Hepatobiliary Surgery, The First Affiliated Hospital of Xi'an Jiaotong University, Xi'an, China

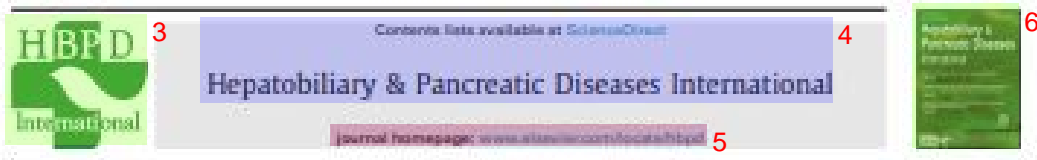Abbreviations

| | |
|------|---|
| LRLN | Left recurrent laryngeal nerve |
| RRLN | Right recurrent laryngeal nerve |
| RLN | Recurrent laryngeal nerve |
| MATT | Magnetic anchoring and traction technique |
| SSC | Stainless-steel cylinder |
| ICS | Intercostal space |
| IASL | Inferior angle of the scapular line |
| PAL | Posterior axillary line |
| AAL | Anterior axillary line |
| MAL | Middle axillary line |
| CWT | Chest wall thickness |
| BMI | Body mass index |

 Springer

10. Magnetic-assisted laparoscopic liver transplantation in swine ¹

Hepatobiliary & Pancreatic Diseases International 21 (2022) 91–96 ²



Original Article on Modern Technology in Liver Surgery and Transplantation ⁷

Magnetic-assisted laparoscopic liver transplantation in swine ⁸

Zhe Feng ^{1,2}, Shan-Pei Wang ², Hao-Hua Wang ³, Qiang Lu ⁴, Wei Qiao ⁴, Kai-Ling Wang ^{1,2,9},
Hong-Fan Ding ^{1,2}, Yue Wang ^{1,2}, Rong-Feng Wang ^{1,2}, Ai-Hua Shi ⁵, Bing-Yi Ren ⁶,
Yu-Nan Jiang ¹, Bin He ¹, Jia-Wei Yu ¹, Rong-Qian Wu ¹, Yi Lv ^{1,2,10} ⁹

¹Department of Hepatobiliary Surgery, the First Affiliated Hospital of Xian Jiaotong University, Xi'an 710001, China
²National Local Joint Engineering Research Center for Precision Surgery in Regenerative Medicine, Shaanxi Provincial Center for Regenerative Medicine and Surgical Engineering, Institute of Advanced Surgical Technology and Engineering, the First Affiliated Hospital of Xian Jiaotong University, Xi'an 710001, China
³Department of Colorectal Surgery, the First Affiliated Hospital of Xian Jiaotong University, Xi'an 710001, China
⁴Department of Hepatobiliary Surgery, Shaanxi Provincial People's Hospital, Xi'an 710000, China
⁵Shanghai College, Xian Jiaotong University, Xi'an 710000, China ¹⁰

ARTICLE INFO ¹¹

Article history: ¹²
Received 8 September 2021
Accepted 23 December 2021 ¹³
Available online 28 December 2021 ¹⁴, ¹⁵
Keywords: ¹⁶
Laparoscopic ¹⁷
Magnetic-assisted ¹⁸
Vascular anastomosis ¹⁹, ²⁰

ABSTRACT ²¹

Background: Although laparoscopic technology has achieved rapid development in the surgical field, it has not been applied to liver transplantation, primarily because of difficulties associated with laparoscopic vascular anastomosis. In this study we introduced a new magnetic-assisted vascular anastomosis technique and explored its application in laparoscopic liver transplantation in pigs. ²²

Methods: Two sets of magnetic vascular anastomosis rings (MVARs) with different diameters were developed. One set was used for anastomosis of the suprahepatic vena cava (SHVC) and the other set was used for anastomosis of the infrahepatic vena cava (IHVC) and portal vein (PV). Six laparoscopic orthotopic liver transplantations were performed in pigs. Donor liver was obtained via open surgery. Hepatectomy was performed in the recipients through laparoscopic surgery. Anastomosis of the SHVC was performed using hand-assisted magnetic anastomosis, and the anastomosis of the IHVC and PV was performed by magnetic anastomosis with or without hand assistance. ²³

Results: Liver transplant were successfully performed in five of the six cases. Postoperative ultrasonographic examinations showed that the portal inflow was smooth. However, PV bending and blood flow obstruction occurred in one case because the MVARs were attached to each other. The duration of loading of MVAR in the laparoscope group and manual assistance group for IHVC and PV were 13 ± 5 vs. 5 ± 1 min ($P = 0.01$) and 10 ± 2 vs. 4 ± 1 min ($P = 0.05$), respectively. The duration of MVAR anastomosis in the laparoscope group and manual assistance group for IHVC and PV were 5 ± 1 vs. 1 ± 1 min ($P = 0.01$), and 5 ± 1 vs. 1 ± 1 min ($P = 0.01$), respectively. The anastomosis phase was 43 ± 4 min in the laparoscope group and 23 ± 2 min in the manual assistance group ($P = 0.01$). ²⁴

Conclusions: Our study showed that magnetic-assisted laparoscopic liver transplantation can be successfully carried out in pigs. ²⁵

© 2022 First Affiliated Hospital, Zhejiang University School of Medicine in China. Published by Elsevier B.V. All rights reserved. ²⁶, ²⁷

Introduction ²⁸

Liver transplantation is the most effective treatment modality for end-stage liver diseases [1]. The operation can be adequately performed through a "J"-shaped incision" or "classic Mercedes incision" [2]. However, there are certain drawbacks, such as com-

plexity of the operation, large incision and long operative time [3]. Moreover, the high rate of incision-related complications after liver transplantation results in a long hospital stay, high cost, and decreased quality of postoperative life [4–6]. Furthermore, surgical site infections caused by multidrug-resistant bacteria are associated with increased morbidity and mortality [3]. In addition, there is no evidence for any conservative intervention that offers significant benefits in reducing wound complications in liver transplantation [7]. ³¹

* Corresponding author at: Department of Hepatobiliary Surgery, the First Affiliated Hospital of Xian Jiaotong University, 277 West Yanta Road, Xi'an 710001, China. E-mail address: lyl@xjtu.edu.cn (Y. Lv).

11. Expert consensus on magnetic recanalization technique for biliary anastomotic strictures after liver transplantation

Viewpoint



Expert consensus on magnetic recanalization technique for biliary anastomotic strictures after liver transplantation

Yu Li^{1,2,3}, Nan Zhang^{2,3}, Yi Lv^{1,2,3}, Scientific Committee of the Third International Conference of Magnetic Surgery*

¹Department of Hepatobiliary Surgery, the First Affiliated Hospital of Xi'an Jiaotong University, Xi'an, China; ²National Local Joint Engineering Research Center for Precision Surgery & Regenerative Medicine, Xi'an, China; ³Shaanxi Province Center for Regenerative Medicine and Surgery Engineering Research, Xi'an, China

Correspondence to: Yi Lv, Department of Hepatobiliary Surgery, the First Affiliated Hospital of Xi'an Jiaotong University, Xi'an 710061, China. Email: luyi169@126.com.

Submitted Nov 16, 2020. Accepted for publication Feb 26, 2021.
doi: 10.21037/hbsn-20-800

View this article at: <http://dx.doi.org/10.21037/hbsn-20-800>

Biliary anastomotic stricture (BAS) is a common complication after liver transplantation.

Endoscopic retrograde cholangiopancreatography (ERCP) or percutaneous transhepatic cholangial drainage (PTCD) is the preferred treatment for BAS. However, these methods are helpless for completely occluded strictures. Magnetic recanalization technology (MRT), which is an application of magnetic compression anastomosis, is reported as a revolutionary way to treat BAS, and initially imply a satisfactory result for complicated cases (1-7). However, there are still no consensus reported. On the Third International Conference of Magnetic Surgery held in Xi'an, experts from various countries have discussed associated fields of MRT in treating BAS and achieved the following consensus.

Indications and contraindications of MRT

Indications

- (I) Biliary anastomotic occlusion, such as bilo-biliary anastomosis and bilo-enteric anastomosis;
- (II) Refractory stricture with multiple failures of ERCP or PTCD;
- (III) Two biliary stricture stumps are close to the same axis.

Absolute contraindications

- (I) The stricture length is >20 mm;
- (II) A large amount of ascites or severe coagulation dysfunction, which do not allow an effective PTCD to be established.

* Members of Scientific Committee of the Third International Conference of Magnetic Surgery (Sorted Alphabetically by Last Name): Michael Avaliani, Blokhin Russian Oncology Research Center, Russian Research Centre of Surgery, Russia; Luigi Bonavina, University of Milan, Istituto di Ricovero e Cura a Carattere Scientifico Policlinico San Donato, Italy; Paolo Cantù, Foundation IRCCS Ca' Granda - Ospedale Maggiore Policlinico, Università degli Studi di Milano, Milan, Italy; Michele Diana, Institut de chirurgie guidée par l'image (IHU) de Strasbourg, Strasbourg, France; Boris Dolgushin, Blokhin Russian Oncology Research Center, Russian Research Centre of Surgery, Russia; Mark Bremholm, Odense University Hospital, Denmark; Takao Itoi, Tokyo Medical University, Japan; Hideaki Kawabata, Kyoto Okamoto Memorial Hospital, Japan; DongKi Lee, Gangnam Severance Hospital, Yonsei University, Korea; Erkan Parlak, Sakarya University, Turkey; Bo Wang, The First Affiliated Hospital of Xi'an Jiaotong University, China; Rong-Qian Wu, The First Affiliated Hospital of Xi'an Jiaotong University, China; Zheng Wu, The First Affiliated Hospital of Xi'an Jiaotong University, China; Xiao-peng Yan, The First Affiliated Hospital of Xi'an Jiaotong University, China; Vitalii Zablotskii, Institute of Physics of the Academy of Sciences of the Czech Republic, Czech.

12. Fast Vascular Reconstruction With Magnetic Devices in Liver Transplant: A Novel Surgical Technique ¹

BRIEF REPORT ²

ZHANG ET AL. ³

Fast Vascular Reconstruction With Magnetic Devices in Liver Transplant: A Novel Surgical Technique ⁴

TO THE EDITOR: ⁵

The vascular anastomosis is one of the most critical steps in transplantation, and the quality of this anastomosis can have a significant impact on posttransplant outcomes. Reconstruction of the suprahepatic and infrahepatic inferior vena cava (IVC), portal vein, as well as the hepatic artery are typically each performed using a hand-sewn technique during liver transplantation (LT). Performing the vascular anastomosis meticulously requires technical expertise and a long learning curve. In fact, even among highly skilled surgeons, vascular suture time can be one of the longest aspects of a LT, and reducing total suture time to below a certain limit is challenging. Revascularizing the liver, however, is time sensitive because minimizing the ischemia time and the anhepatic period is critical to reducing

allograft dysfunction, intestinal bacterial translocation, and acute liver failure.⁽¹⁾ ¹⁶

Given the limitations of the traditional hand-sewn vascular anastomosis techniques, we sought to develop a novel approach to facilitate a fast and safe technique to perform the vascular anastomosis during transplantation by using magnetic devices.^(2,3) Specifically, we herein characterize a new magnetic device that can be successfully used for major vascular reconstruction among LT patients. ¹⁷

Patients and Methods ¹⁸

MAGNETIC DEVICE ¹⁹

The magnetic device for vascular anastomosis during LT consisted of a pair of C-shaped magnetic rings and matched base members. The magnetic rings are made of neodymium-ferrom-boron and coated with titanium nitride (Fig. 1A,B). The base members were made of a polymer material and had a C-shaped base body with a central through slot and a C-shaped protrusion integrally (Fig. 1A,B). ²⁰

On the C-shaped base member, 8 radial holes were outwardly and evenly distributed at the outer circumferential portion of the base body to allow for suturing fixation of the vascular wall. The C-shaped magnetic rings and the C-shaped base member formed a complete O-shaped ring after pairing (Fig. 1A,B). ²¹

PATIENT INCLUSION ²²

Patients undergoing orthotopic LT using donation after circulatory death between November 2018 and December 2019 in our hospital were included. Patients were excluded from the study group if they were ≤ 18 or ≥ 70 years old, had major vascular thrombosis, were retransplants, or were unwilling to attend the study. Only patients who were eligible for and who volunteered to be included in the magnet-assisted LT were finally included in the study and ²³

Abbreviations: CIT, cold ischemia time; HTK, histidine-tryptophan-ketoglutarate; IQR, interquartile range; IVC, inferior vena cava; LT, liver transplantation; UW, University of Wisconsin; WIT, warm ischemia time. ⁷

Additional supporting information may be found in the online version of this article. Address reprint requests to Yi Lv, M.D., Ph.D., Department of Hepatobiliary Surgery and Institute of Advanced Surgical Technology and Engineering, The First Affiliated Hospital of Xi'an Jiaotong University, Xi'an, Shaanxi Province, 710061, China. Telephone: +86 29 85323904; FAX: +86 29 85252580; E-mail: luyi169@xjtu.edu.cn ⁸

This study was supported by the National Natural Science Foundation of China (30830099, 81470896, and 81127005) and the Shaanxi Provincial Scientific Program (2017CGZH-HJ-14). ⁹

These authors contributed equally to this work. ¹⁰

Received June 22, 2020; accepted August 29, 2020. ¹¹

Copyright © 2020 by the American Association for the Study of Liver Diseases. ¹²

View this article online at wileyonlinelibrary.com. ¹³

DOI 10.1002/lt.25889 ¹⁴

Potential conflict of interest: Nothing to report. ¹⁵

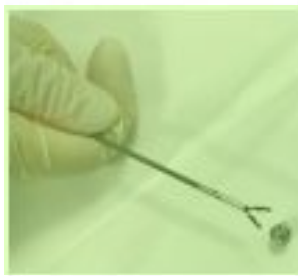
13. Magnetic multidirectional anchor-guided endoscopic submucosal tunnel dissection

Article published online: 2020-12-09

Volume 3

Theme 4

Magnetic multidirectional anchor-guided endoscopic submucosal tunnel dissection for large gastric lesions



► Fig. 1 Photograph of the iron-shielded magnet, which is attached to a hemoclip with dental floss.

Magnetic anchor-guided endoscopic submucosal dissection (MAG-ESD) using an extracorporeal electromagnetic was developed to provide excellent visualization and to facilitate complicated ESD in patients with early gastric cancer (EGC), with its use being reported in several studies over recent years [1–3]. Endoscopic submucosal tunnel dissection (ESTD) has been reported as a treatment

for the en bloc dissection of large early neoplastic lesions with higher dissection speed and better radical cure rates than standard ESD [4, 5]. This case report describes a new method, magnetic multidirectional anchor-guided ESTD (MMAG-ESTD), for the treatment of large EGCs in human subjects. A 54-year-old woman was referred to our hospital with a high grade intraepithelial neoplasia extending from the gastric angle to the fundus. MMAG-ESTD was performed using a gastroscope fitted with a soft transparent front cap. The magnetic anchor-guided system consists of an interior magnet made of an Nd2Fe14B crystal, with a shell of pure iron, and an internal device, which is a medical stainless steel column of 10 × 10 mm (► Fig. 1).

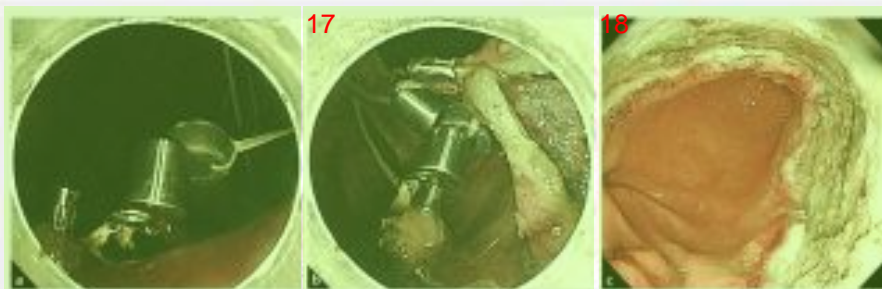After a partial mucosa cut was made transversely with a DualKnife, one magnetic anchor consisting of an internal neodymium magnet with a hemoclip was attached to the proximal mucosal edge of the lesion (► Fig. 2a). A submucosal tunnel was then created by submucosal dissection from the proximal to the distal end. Unlike previous magnetic devices,

this system requires no external magnets, which makes the entire procedure simpler. The other two shells with hemoclips were attached to the horizontal mucosal edge, which then attracted the internal magnet, with adequate countertraction to create good visualization, thereby assisting the submucosal dissection procedure (► Fig. 2b). The mucosal countertraction fully exposed the submucosal field of vision in three directions. MMAG-ESTD was successful performed without adverse events (► Fig. 2c; ► Video 1). By combining the advantages of both magnetic ESD and tunnel ESD, we hope that this MMAG-ESTD system will facilitate difficult ESD procedures and enhance the field of magnetic endoscopic surgery in future.

Endoscopy_UCIN_Code_TTT_1A0_2AG

Competing interests

The authors declare that they have no conflict of interest.



► Fig. 2 Endoscopic views showing: a) after partial dissection, the mucosal edge with the magnetic anchor attached; b) direct visualization of the submucosal layer that is achieved by traction via the magnetic shell; c) the large artificial ulcer left after magnetic multidirectional anchor-guided endoscopic submucosal tunnel dissection.

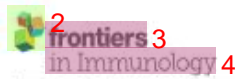
E132 21

Lin, Dingqun et al. Magnetic multidirectional anchor-guided ESTD ... Endoscopy 2021; 53: 1382–1384 | © 2020 Thieme. All rights reserved.

22

Downloaded by Xi'an Jiaotong University. Copyrighted material

14. Innate Immune Regulation Under Magnetic Fields With Possible Mechanisms and Therapeutic Applications ¹



REVIEW
published: 22 October 2020
doi: 10.3389/fimmu.2020.582772



Innate Immune Regulation Under Magnetic Fields With Possible Mechanisms and Therapeutic Applications ⁹

Hong Lei ^{1*}, Yi Pan ², Rongqian Wu ¹ and Yi Lv ^{1,3*} ²⁷

OPEN ACCESS ¹⁰

¹¹ Edited by:
Alexandre Cortay,
Oslo University Hospital, Norway

¹² Reviewed by:
Malgorzata Kibac,
Houston Methodist Research Institute,
United States
Anil Shanker,
Maharaja Medical College,
United States
Bagonya Corin-Anulita,
UCLA David Geffen School of
Medicine, United States
Tufan Mert,
Abant İzzet Baysal University, Turkey

¹³ *Correspondence:
Hong Lei
hongleil@xjtu.edu.cn
Yi Lv
Lvy169@126.com

¹⁴ Specialty section:
¹⁵ This article was submitted to
¹⁶ Molecular Innate Immunity,
¹⁷ a section of the journal
¹⁸ Frontiers in Immunology

¹⁹ Received: 21 July 2020
²⁰ Accepted: 28 September 2020
²¹ Published: 22 October 2020

²² Citation:
²³ Lei H, Pan Y, Wu R and Lv Y (2020)
²⁴ Innate Immune Regulation
²⁵ Under Magnetic Fields With
²⁶ Possible Mechanisms and
²⁷ Therapeutic Applications.
²⁸ Front. Immunol. 11:582772.
²⁹ doi: 10.3389/fimmu.2020.582772

³⁰ ¹⁰ National Local Joint Engineering Research Center for Precision Surgery and Regenerative Medicine, The First Affiliated Hospital of Xi'an Jiaotong University, Xi'an, China, ¹¹ Center for Spintronics and Quantum Systems, State Key Laboratory for Mechanical Behavior of Materials, Xi'an Jiaotong University, Xi'an, China, ¹² Department of Hepatobiliary Surgery, The First Affiliated Hospital of Xi'an Jiaotong University, Xi'an, China

¹³ With the wide applications of magnetic fields (MFs) in medicine, researchers from different disciplines have gained interest in understanding the effect of various types of MFs on living cells and organisms. In this paper, we mainly focus on the immunological and physical aspects of the immune responses and their mechanisms under different types of MFs. Immune cells were slightly affected by low-frequency alternating MFs but were strongly influenced by moderate-intensity MFs and high-gradient MFs (HGMFs). Larger immune cells, such as macrophages, were more sensitive to HGMFs, which biased the cell polarization into the anti-inflammatory M2 phenotype. Subject to the gradient forces of varying directions and strength, the elongated M2 macrophage also remodeled the cytoskeleton with actin polymerization and changed the membrane receptors and ion channel gating. These alterations were very similar to changes caused by the small GTPase RhoA interference in macrophages. Regulation of iron metabolism may also contribute to the MF effects in macrophages. High MFs were found to regulate the iron content in monocyte-/macrophage-derived osteoclasts by affecting the expression of iron-regulation genes. On the other hand, paramagnetic nanoparticles (NPs) combined with external MFs play an important role in T-cell immunity. Paramagnetic NP-coated T-cells can cluster their T-cell receptors (TCRs) by using an external MF, thus increasing the cell-cell contact and communication followed by enhanced tumor killing capacity. The external MF can also guide the adoptively transferred magnetic NP-coated T-cells to their target sites *in vivo*, thus dramatically increasing the efficiency of cell therapy. Additionally, iron oxide NPs for ferroptosis-based cancer therapy and other MF-related therapeutic applications with obstacles were also addressed. Furthermore, for a profound understanding of the effect of MFs on immune cells, multidisciplinary research involving both experimental research and theoretical modeling is essential.

³⁰ **Keywords:** innate immune regulation, magnetic fields, macrophages polarization, iron metabolism, paramagnetic nanoparticles

15. Magnetic spiderman, a new surgical training device: study of safety and educational value in a liver transplantation surgical training program

World J Surg ²
<https://doi.org/10.1007/s00268-019-05300-8> ³



ORIGINAL SCIENTIFIC REPORT

Magnetic Spiderman, a New Surgical Training Device: Study of Safety and Educational Value in a Liver Transplantation Surgical Training Program

Yue Wang^{1,2} · Huan Chen^{1,2} · Bo Tang¹ · Tao Ma^{1,2} · Qingshan Li^{1,2} · Haoyang Zhu^{1,2} · Xiaogang Zhang² · Yi Lv^{1,2} · Dinghui Dong^{1,2}

© Société Internationale de Chirurgie 2019 ⁹

Abstract ¹⁰

Introduction Difficulties with liver transplantation (LT)-related surgical techniques are great challenges for young surgeons. Thus, young surgeons need to undergo systematic preclinical training. However, an optimal training system for LT is still lacking. This study aims to evaluate the safety and educational value of the Magnetic Spiderman (MS) during LT-related surgical techniques training, particularly during training for the preparation of the donor's liver and vascular reconstruction.

Methods For the donor liver preparation training, the pulling force of the MS was measured using 16 porcine livers. Another 40 porcine livers were divided into two groups: MS group (used MS in the preparation of the liver) ($n = 25$) and manual group (took manual assistance in the preparation of the liver) (MA group, $n = 15$). In vascular reconstruction training, 25 pairs of porcine iliac veins were used to practice reconstruction. Five LT experts evaluated the MS for its use in LT-related surgical techniques training.

Results During the donor liver preparation training, the number of assistants required in the MS group was significantly less than the number required in the MA group (0 vs. 1.8 ± 0.1 ; $P < 0.001$). However, the number of vasculature leaking points was similar between the two groups (0.2 ± 0.1 vs. 0.4 ± 0.2 ; $P = 0.51$). In vascular reconstruction training, the trainee alone could complete the vascular reconstruction training, with a reconstruction success rate of 80% (20/25). All five experts considered the MS a viable alternative to assistants, with the ability to facilitate single surgeon training for LT. Four out of five (80%) experts considered MS quite safe for surgery and effective at keeping the surgical field clear.

Conclusion MS can reduce the number of assistants to zero in LT-related techniques training without increasing the risk of the operation, thus facilitating training for LT.

Introduction ¹⁵

Liver transplantation (LT) is the most effective therapy for patients with end-stage liver diseases and greatly improves the survival time of patients [1–4]. Although the first LT was performed by Dr. Starzl 50 years ago, the associated technical difficulties are still great challenges for young surgeons [5, 6]. Thus, a young surgeon needs to receive systematic preclinical training [7]. The basic steps in LT are the procurement, preparation, and implantation of the liver to the recipient [8]. The surgical techniques for the procurement of the liver are similar to those required for

✉ Yi Lv ¹⁶
Luyi169@126.com ¹⁷

✉ Dinghui Dong ¹⁸
dongdinghui1988@stu.xjtu.edu.cn ¹⁹

¹ National Local Joint Engineering Research Center for Precision Surgery and Regenerative Medicine, First Affiliated Hospital of Xi'an Jiaotong University, No. 76, West Yanta Road, Xi'an 710061, Shaanxi Province, China ²⁰

² Department of Hepatobiliary Surgery, First Affiliated Hospital of Xi'an Jiaotong University, No. 277, West Yanta Road, Xi'an 710061, Shaanxi Province, China

Published online: 27 November 2019



16. Effects of different 980-nm diode laser parameters in hepatectomy ¹

Lasers in Surgery and Medicine ²

Effects of Different 980-nm Diode Laser Parameters in Hepatectomy ³

Tao Ma,^{1,2} Yi-Chao Chai,^{1,3} Hao-Yang Zhu,^{1,2} Huan Chen,^{1,2} Yue Wang,^{1,2} Qing-Shan Li,^{1,2} Li-Hui Pang,¹ Rong-Qian Wu,¹ Yi Lv,^{1,2} and Ding-Hui Dong^{1,2} ⁴

¹National Local Joint Engineering Research Center for Precision Surgery & Regenerative Medicine, First Affiliated Hospital of Xi'an Jiaotong University, Xi'an, 710061, China ⁵

²Department of Hepatobiliary Surgery, First Affiliated Hospital of Xi'an Jiaotong University, Xi'an, 710061, China ⁶

³Department of Surgical Oncology, Second Affiliated Hospital of Xi'an Jiaotong University, Xi'an, 710004, China

Background and Objective: Despite the successful application of laser in animal experiments and clinics, the adjustment of laser parameters during surgery is still unclear. This study aimed to investigate the effect of different 980-nm diode laser parameters in hepatectomy. This could provide a clear protocol for using 980-nm diode laser in hepatectomy.

Study Design/Materials and Methods: In total, 48 Sprague–Dawley rats were used to explore the effects of different 980-nm diode laser parameters in hepatectomy, by setting different parameter combinations. The rats were randomly divided into eight groups, including the continuous wave group and quasi-continuous wave group. The effects were assessed in terms of liver resection speed, extent of intraoperative bleeding, and thermal damage.

Results: In the quasi-continuous wave group, there was a significant difference in resection speed at the different laser parameters ($P < 0.001$); however, there was no significant difference in intraoperative bleeding and thermal damage. In the continuous wave group, there was a significant difference in resection speed, intraoperative bleeding, and thermal damage at different parameters.

Conclusion: The study showed that the average power determined hemostasis efficiency and thermal damage, and peak power determined the liver resection speed, whereas the pulse width and repetition frequency are not independent factors. When using 980-nm diode laser in hepatectomy, the average power should be decreased to prove hemostasis efficiency in delicate operations, and the peak power should be decreased to accelerate the procedure without worsening thermal damage. *Lasers Surg. Med.* 1–8, 2018. © 2019 Wiley Periodicals, Inc.

Key words: 980-nm diode laser; hepatectomy; laser parameters; resection efficiency

INTRODUCTION ¹²

Laser is a promising surgical instrument, as it can be used to simultaneously cut and coagulate a tissue without contacting it, thus, offering a bloodless operating field

[1–3]. Solid-state laser and gas laser were more commonly used in the past, whereas diode laser was subsequently developed. The diode laser has obvious advantages such as a simple structure, ability to deliver a more stable performance, lower cost, and higher efficiency of electro-optic conversion. Laser has broad applications in the surgical field, especially in prostate resection [4,5], myomectomy [6], lung surgery [7,8], partial nephrectomy [9], and oral soft tissue resection [10].

Hepatobiliary surgery would be the next emerging field of application of laser surgery. In recent years, laser-induced interstitial thermotherapy, which is based on laser thermal effect, has emerged as a new minimally invasive technique for liver ablation [11,12]. However, in hepatectomy, laser is still not widely used. As the liver is a blood-rich solid organ, not only precision and efficiency but also effective control of bleeding are imperative during the operation. The most commonly used surgical equipment in liver resection is high-frequency electro-tome and ultrasonically activated scalpel [13,14]. The 980-nm diode laser, as a new type of surgical laser tool, is suitable for liver resection, because its wavelength is highly absorbed in hemoglobin and water, leading to a higher efficacy and lower risk of damage [15]. Although many pilot studies have confirmed its effectiveness in hepatectomy, its wide clinical application is still underway [16].

Conflict of Interest Disclosures: All authors have completed and submitted the ICMJE Form for Disclosure of Potential Conflicts of Interest and none were reported. Contract grant sponsor: Ministry of Education Innovation Team Development Program of China; Contract grant number: IRT16R57; Contract grant sponsor: Shaanxi Provincial Key Research and Development Program; Contract grant number: 2018ZDXM-SF-080; Contract grant sponsor: Fundamental Research Funds for the Central Universities; Contract grant number: xj2018288.
*Correspondence to: Ding-Hui Dong, MD, PhD, and Yi Lv, MD, PhD, National Local Joint Engineering Research Center for Precision Surgery & Regenerative Medicine, First Affiliated Hospital of Xi'an Jiaotong University, No. 76 West Yanta Road, Xi'an, Shaanxi Province 710061, China. E-mail: dongdinghui1988@stu.xjtu.edu.cn (D.-H.D.); luyi169@126.com (Y.L.)

Accepted 23 April 2019
Published online in Wiley Online Library ¹⁸
(wileyonlinelibrary.com) ¹⁹
DOI 10.1002/lsm.23101 ²⁰
²¹

17. 10-mm laparo-endoscopic single-site cholecystectomy using multiple magnetically anchored and controlled instruments

JOURNAL OF SURGICAL RESEARCH • JULY 2019 (239) 166–172



ELSEVIER

Available online at www.sciencedirect.com

ScienceDirect

journal homepage: www.JournalofSurgicalResearch.com



10-mm Laparo-Endoscopic Single-Site Cholecystectomy Using Multiple Magnetically Anchored and Controlled Instruments

Haoyang Zhu, MD,^{a,b} Yafei Shang, MD, PhD,^b Tao Ma, MD,^{a,b} Yue Wang, MD,^{a,b} Rongqian Wu, MD, PhD,^b Yi Lv, MD, PhD,^{a,b,**} and Dinghui Dong, MD, PhD^{a,b,*}

^a Department of Hepatobiliary Surgery, First Affiliated Hospital of Xi'an Jiaotong University, Xi'an, Shaanxi, China

^b National Local Joint Engineering Research Center for Precision Surgery and Regenerative Medicine, First Affiliated Hospital of Xi'an Jiaotong University, Xi'an, Shaanxi, China

ARTICLE INFO

Article history: 15
Received 23 October 2018 16
Received in revised form 17
22 January 2019 18
Accepted 6 February 2019 19
Available online xxx 20

Keywords: 21
Magnetically anchored camera 22
Magnetically anchored grasper 23
system 24
LESS 25
Cholecystectomy 26
Minimally invasive surgery 27
Laparo-endoscopic single-site 28
surgery 29

ABSTRACT

Background: To study the feasibility of laparo-endoscopic single-site (LESS) cholecystectomy through a 10-mm incision using a miniature magnetically anchored and controlled laparoscopy system and a grasper system. 31
Methods: The miniature magnetically anchored and controlled laparoscopy system consisted of a miniature magnetically anchored camera (MMAC), an external magnetic anchoring unit, and a vision output device. The camera weighed 9.8 g and measured $\Phi 10 \text{ mm} \times 50 \text{ mm}$. The magnetically anchored and controlled grasper system consisted of a magnetically anchored grasper (MAG), an external magnetic anchoring unit, and a push-pull device. The MAG had a titanium alloy clip head and a magnetic tail. The laparoscopy system and grasper system were used simultaneously to perform LESS cholecystectomy through a single 10-mm incision in model canines. 32
Results: LESS cholecystectomy through a 10-mm incision using the MMAC and MAG was attempted in six dogs. The mean operative time was $85.75 \pm 7.14 \text{ min}$. The operation was completed successfully in four cases, with failure occurring in one case due to gallbladder rupture and in another due to bile duct injury. The MMAC provided clear imaging, and the MAG provided sufficient exposure to perform the cholecystectomy. The use of multiple magnetically anchored and controlled instruments did not result in notable collisions. 33
Conclusions: The designed MMAC and MAG system could be easily maneuvered. LESS cholecystectomy may be feasible through a single 10-mm incision with the simultaneous use of multiple magnetically anchored and controlled instruments. 34

© 2019 Elsevier Inc. All rights reserved.

* Corresponding author. Department of Hepatobiliary Surgery, First Affiliated Hospital, Xi'an Jiaotong University, 76 West Yanta Road, Xi'an, Shaanxi 710061, China. Tel.: +8615129011093; fax: +86 29-85323900. 35

** Corresponding author. National Local Joint Engineering Research Center for Precision Surgery and Regenerative Medicine, Shaanxi 710061, China. Tel./fax: +86 29-82657541. 36

E-mail addresses: dongdinghui1988@stu.xjtu.edu.cn (D. Dong), luyi169@126.com (Y. Lv) 37

0022-4804/\$ – see front matter © 2019 Elsevier Inc. All rights reserved. 38

<https://doi.org/10.1016/j.jss.2019.02.012> 39

18. A sutureless method for digestive tract reconstruction during pancreaticoduodenectomy in a dog model ¹

Int J Clin Exp Med 2015;8(1):289-296 ²
www.ijcem.com /ISSN:1940-5901/IJCEM0003665 ³

Original Article ⁴

A sutureless method for digestive tract reconstruction during pancreaticoduodenectomy in a dog model ⁵

Xiaohai Cu^{1,2}, Peng Lei³, Shiqi Liu³, Xuemin Liu³, Zheng Wu³, Yi Lv⁶ ⁶

¹Institute of Advanced Surgical Technology and Engineering, Xi'an Jiaotong University, Xi'an 710061, China; ²Second Department of Thoracic Surgery, The First Affiliated Hospital of Xi'an Jiaotong University, Xi'an 710061, China; ³Department of Hepatobiliary Surgery, The First Affiliated Hospital of Xi'an Jiaotong University, Xi'an 710061, China

Received November 7, 2014; Accepted January 10, 2015; Epub January 15, 2015; Published January 30, 2015 ⁸

Abstract: Development of pancreatic fistulas as a result of anastomotic gaps is still a major complication after pancreaticoduodenectomy, and can cause post-operative death. Therefore, safer and more effective methods of anastomosis are needed to avoid leakage and decrease mortality. Materials and methods: Twenty domestic dogs with body weights ranging from 15 to 25 kg were used, regardless of gender. A model of common bile duct and pancreatic duct dilatation was surgically prepared in these dogs. Pancreaticobiliary stents combined with magnetic anastomoses (PB-MA), and controls were treated with fibrin glue were studied in terms of and efficacy by measurement of serum amylase, incidence of complications, and survival times. Results: The mean time required to create the fibrin glue pancreaticoenterostomy was 9 ± 2.05 min, while the mean time required to create the magnet cholangioenterostomy was 5 ± 0.9 min. The total operative time was 2.7 ± 0.6 h. Eighty percent of the dogs that underwent the operations were still alive for 15 days after the operations and none developed pancreatic fistulas. Examination by macroscopic observation, and hematoxylin and eosin staining of the pathological specimens showed that the anastomoses were completely healed. Conclusions: The use of a PB-MA in sutureless digestive tract reconstruction for pancreaticoduodenectomy resulted in an elimination of pancreatic fistulas, and shortening of the stent removed time. In addition, the procedure is simple to perform, fast, and appears to be safe in this dog model. ⁹

Keywords: Pancreatic fistula, pancreaticoduodenectomy, magnetic sutureless anastomosis ¹⁰

Introduction ¹¹

Although, pancreaticoduodenectomy has improved dramatically as a therapeutic operation for the treatment of carcinoma of the head of pancreas, ampulla and chronic pancreatitis, there are still many deficiencies. Pancreatic fistula (PF) continues to be a major complication, ranging from 3% to 26% [1-7], usually caused by inadequate anastomosis, long operation time, and prolonged requirement for internal stents. To solve these problems, surgeons have attempted to improve the operative technique using binding pancreaticojejunostomies [8], external or internal stents [9, 10] and pancreaticogastrostomies [7, 11]. However, these techniques are not widely applicable. Moreover, they have not significantly decreased the incidence of complications. ¹²

Previous studies have showed that PF is caused by gaps in sutured anastomoses, due to ¹³

increased pressure in the jejunal lumen, and digestion by pancreatin which is activated by bile and intestinal juice. Roux-en-Y choledochojejunostomy is a common operation for bypassing extrahepatic biliary obstructions and establishing biliary-enteric continuity after resections for benign or malignant biliary diseases [12, 13]. The traditional procedure is also time consuming which may also be directly related to the PF: 1. The potential gaps between the sutures of the anastomosis can enable pancreatic juice to leak out; 2. Postoperatively, bile and pancreatic juice frequently accumulate in the jejunal lumen, leading to increases in anastomotic tension, which can cause a pancreatic fistula; 3. The location of the suture can result in poor blood supply and healing; 4. Bile mixed with pancreatic juice in the jejunal lumen after operation can activate trypsin resulting in digestion of the anastomosis. Although stapled anastomoses have been used in an attempt to ¹⁴

19. Performance of physical examination skills in medical students¹ during diagnostic medicine course in a University Hospital of Northwest China

OPEN ACCESS Freely available online



Performance of Physical Examination Skills in Medical Students during Diagnostic Medicine Course in a University Hospital of Northwest China²



Yan Li, Na Li, Qunying Han, Shuixiang He, Ricard S. Bae, Zhengwen Liu*, Yi Lv, Bingyin Shi³

First Affiliated Hospital, School of Medicine, Xi'an Jiaotong University, Shaanxi, Xi'an, China⁴

Abstract⁵

This study was conducted to evaluate the performance of physical examination (PE) skills during our diagnostic medicine course and analyze the characteristics of the data collected to provide information for practical guidance to improve the quality of teaching. Seventy-two fourth-year medical students were enrolled in the study. All received an assessment of PE skills after receiving a 17-week formal training course and systematic teaching. Their performance was evaluated and recorded in detail using a checklist, which included 5 aspects of PE skills: examination techniques, communication and care skills, content items, appropriateness of examination sequence, and time taken. Error frequency and type were designated as the assessment parameters in the survey. The results showed that the distribution and the percentage in examination errors between male and female students and among the different body parts examined were significantly different ($p < 0.001$). The average error frequency per student in females (0.875) was lower than in males (1.375) although the difference was not statistically significant ($p = 0.167$). The average error frequency per student in cardiac (1.267) and pulmonary (1.389) examinations was higher than in abdominal (0.867) and head, neck and nervous system examinations (0.917). Female students had a lower average error frequency than males in cardiac examinations ($p = 0.041$). Additionally, error in examination techniques was the highest type of error among the 5 aspects of PE skills irrespective of participant gender and assessment content ($p < 0.001$). These data suggest that PE skills in cardiac and pulmonary examinations and examination techniques may be included in the main focus of improving the teaching of diagnostics in these medical students.

Citation: Li Y, Li N, Han Q, He S, Bae RS, et al. (2014) Performance of Physical Examination Skills in Medical Students during Diagnostic Medicine Course in a University Hospital of Northwest China. PLoS ONE 9(10): e109294. doi:10.1371/journal.pone.0109294⁷

Editor: Aamir Ahmed, University College London, United Kingdom⁸

Received: February 11, 2014; **Accepted:** September 10, 2014; **Published:** October 15, 2014⁹

Copyright: © 2014 Li et al. This is an open-access article distributed under the terms of the Creative Commons Attribution License, which permits unrestricted use, distribution, and reproduction in any medium, provided the original author and source are credited.¹⁰

Funding: Yan Li was supported by the First Affiliated Hospital, School of Medicine, Xi'an Jiaotong University and 10000 Women: The Yale-Tsinghua Certificate Program in International Healthcare Management. The funders had no role in study design, data collection and analysis, decision to publish, or preparation of the manuscript.¹¹

Competing Interests: The authors have declared that no competing interests exist.¹²

* Email: liuzhengwen@medmail.com.cn¹³

Introduction¹⁴

Diagnostic medicine plays an important role in bridging basic medicine and clinical medicine [1,2]. The content of diagnostics includes inquiry, physical examination, laboratory examination and other ancillary examinations. The abilities acquired with regards to diagnostics accompany a doctor through his or her entire career, from medical school to internship to clinical practice.

Physical examination (PE) skills are basic and essential elements of clinical competency for medical staff [3]. In PE, one of the four clinical diagnostic methods, physicians use their senses and traditional tools, such as thermometer, sphygmomanometer, percussion hammer, and stethoscope, to objectively understand and systematically assess the patient, and discover normal and abnormal signs. PE skills are the mainstay of clinical diagnosis in rural hospitals, where physical and financial access to other tests is extremely limited. Performing a proper physical examination using four modalities (inspection, palpation, percussion and auscultation) also provides the physical contact that communicates a doctor's caring touch to the patient. In a recent study, performance of the general physical examination was shown to be already below expectation at the end of the internal medicine

clerkship [4]. However, no grave concern over medical students' performance of PE skills during their diagnostic medicine course has been addressed.¹⁷

Chinese medical students are required to systematically learn PE skills for the first time during their diagnostic medicine course. The objective of this study was to conduct an investigation on the performance of PE skills during their diagnostic medicine course and analyze the characteristics of the data collected to provide information for practical guidance to improve the quality of teaching.¹⁸

Methods¹⁹

Ethics Statement²⁰

This study was approved by the Institutional Research Ethics Board of the First Affiliated Hospital, School of Medicine, Xi'an Jiaotong University. All participants provided their written informed consent to participate in this study and this consent procedure was approved by the Institutional Research Ethics Board.²¹

20. Mechanical design of wireless in vivo robot unit for surgical vision ¹

Proceedings of 2014 IEEE ²
International Conference on Mechatronics and Automation ³
August 3 - 6, Tianjin, China ⁴

Mechanical Design of Wireless In Vivo Robot Unit ⁵ for Surgical Vision

Xingyang Liu, Haibo Feng and Yili Fu ⁶
State Key Laboratory of Robotics and System ⁷
Harbin Institute of Technology ⁸
Harbin, Heilongjiang 150080, China ⁹
email_lxy@126.com ¹⁰

Yi Lv ¹¹
Department of Hepatobiliary Surgery ¹²
The First Affiliated Hospital of Xi'an Jiaotong University ¹³
Xi'an, Shanxi 710061, China ¹⁴
Luyi169@126.com ¹⁵

Abstract - Compared to the traditional open surgery, minimally invasive abdominal surgery results in improved results. In order to further reduce the number of incisions, some people put forward laparoendoscopic single-site surgery (LESS) which can get better results. But it also has several disadvantages, such as the tools' interference with each other, the restriction of tools' motion space due to incision. The tools which are able to work in the abdominal cavity entirely can overcome the disadvantages mentioned above, they are ideal for the LESS. We are working on a kind of in vivo robot unit which works entirely in the abdominal cavity. It has the function of lighting and visual feedback. For the purpose of providing better surgical field, the robot unit can tilt to a certain angle and clean the lens automatically. This paper focuses on introducing the design procedure of key transmission parts, self-cleaning executive mechanism and shells.

Index Terms - laparoendoscopic single-site surgery, vision, lighting, in vivo ¹⁷

I. INTRODUCTION ¹⁸

Compared to the traditional surgical procedures, laparoscopy has the advantages of less pain, less surgical complications, quicker recovery and so on, therefore, it draws a lot of attention and develops a lot. Nowadays, laparoscopy has become the preferred way to deal with procedure of cholecystectomy and appendectomy [1]. However, it has several disadvantages, such as the bad operability because of its inherent flexibility, lack of feel and vision feedback. Surgeons want to get better results by future reducing the number of incisions, and put forward laparoendoscopic single-site surgery (LESS) and natural orifice transluminal endoscopic surgery (NOTES) [2,3]. There is no apparent scar in the procedure of LESS, it is meaningful for patients, but just because of the single site, the operating space is restricted seriously. NOTES is likely the most advanced surgical approach, there are no incisions in the surface of patient's body [4-6]. Instead, the incisions are placed on the visceral wall. It is more difficult to manipulate for the surgeons, and there is the risk of disclosure. Therefore, NOTES is full of challenges.

As the development of robotics, robots are applied to the field of medical treatment. In the beginning, the mature technologies of industrial robots are used to help locate precisely and assist with surgical procedures, and then the surgical robot developed a lot in the past decades [7]. Advantages of surgical robots include tremor reduction,

motion scaling, additional articulations and stereoscopic vision. Among these surgical robots, Da Vinci Surgical System has become an outstanding representative. However, these robots are all working outside the patients, the restriction owing to the incision still exists. In addition, these robots are heavy and expensive [8-10]. ²¹

In order to eliminate the restriction of incision, some people start to develop the in vivo robots which work entirely in the abdominal cavity [11]. If several in vivo robot units are placed into the abdominal cavity, they can cooperate to accomplish different kinds of surgical operations without the restriction of incision [12-18]. To place the units in the right position, Magnetic Anchoring and Guidance System (MAGS) is proposed [19]. Some researches have shown that the MAGS does not damage the tissue of abdominal wall [20]. ²²

Now we are focusing on developing a kind of wireless in vivo micro robot unit which has the function of lighting and vision feedback. MAGS is used to guide the unit to the right position. Considering surgeon's need of surgical field, the unit can tilt the angle of camera. In addition, sometimes there is water mist and other stain on the surface of lens, and it will infect image quality. To remove the water mist and stain, the unit has self-cleaning mechanism. The advantages of the unit we are developing include: working entirely in the abdominal cavity to eliminate the restriction of incision and save the space of trocar for other surgical tools; being able to reach any place of abdominal cavity to provide good lighting condition and proper imaging angle. ²³

Compared with other in vivo robots, the characteristic of ours is the function of self-cleaning. ²⁴

II. DESIGN ²⁵

Because the unit we developed will work in the abdominal cavity, the size of unit must be controlled strictly. In the procedure of designing, we need to consider several factors, such as the shape and size of camera modular, control modular and battery, the kind of actuator, besides, the position of unit's different parts should be arranged opportunely. Fig. 1 shows the final scheme of the unit. ²⁶